




A Role for the Inflammasome in Spontaneous Preterm Labor With Acute Histologic Chorioamnionitis

Reproductive Sciences
2017, Vol. 24(10) 1382-1401
© The Author(s) 2017
Reprints and permission:
sagepub.com/journalsPermissions.nav
DOI: 10.1177/1933719116687656
journals.sagepub.com/home/rsx


Nardhy Gomez-Lopez, MSc, PhD^{1,2,3}, Roberto Romero, MD, DMedSci^{1,4,5,6},
Yi Xu, PhD^{1,2}, Olesya Plazyo, MSc^{1,2}, Ronald Unkel, BSc^{1,2},
Yaozhu Leng, MSc^{1,2}, Nandor Gabor Than, MD, PhD^{1,7,8,9},
Tinnakorn Chaiworapongsa, MD^{1,2}, Bogdan Panaitescu, MD, PhD^{1,2},
Zhong Dong, PhD^{1,2}, Adi L. Tarca^{1,2}, Vikki M. Abrahams, PhD¹⁰,
Lami Yeo, MD^{1,2}, and Sonia S. Hassan, MD^{1,2}

Abstract

Inflammasomes are cytosolic multiprotein complexes that orchestrate inflammation in response to pathogens and endogenous danger signals. Herein, we determined whether the chorioamniotic membranes from women in spontaneous preterm labor with acute histologic chorioamnionitis (1) express major inflammasome components; (2) express caspase (CASP)-1 and CASP-4 as well as their active forms; (3) exhibit apoptosis-associated speck-like protein containing a CARD (ASC)/CASP-1 complex formation; and (4) release the mature forms of interleukin (IL)-1 β and IL-18. We utilized quantitative reverse transcription polymerase chain reaction, enzyme-linked immunosorbent assay, immunoblotting, and immunohistochemistry to determine the messenger RNA (mRNA) and protein expression of major inflammasome components, nucleotide-binding oligomerization domain (NOD) proteins, and the pro- and mature/active forms of CASP-1, CASP-4, IL-1 β , and IL-18. The ASC/CASP-1 complex formation was determined using an in situ proximity ligation assay. When comparing the chorioamniotic membranes from women in spontaneous preterm labor with acute histologic chorioamnionitis to those without this placental lesion, we found that (1) the mRNA of NLR family pyrin domain-containing protein (*NLRP1*), *NLRP3*, NLR family CARD domain-containing protein 4 (*NLR4*), and *NOD2* were higher; (2) the *NLRP3* protein was increased; (3) the mRNA and active form (p10) of CASP-1 were greater; (4) the mRNA and active form of CASP-4 were increased; (5) the mRNA and mature form of IL-1 β were higher; (6) the mature form of IL-18 was elevated; and (7) ASC/CASP-1 complex formation was increased. In conclusion, spontaneous preterm labor with acute histologic chorioamnionitis is characterized by an upregulation of *NLRP3* and the active form of CASP-4, as well as increased ASC/CASP-1 complex formation, which may participate in the activation of CASP-1 and the maturation of IL-1 β and IL-18 in the chorioamniotic membranes. These findings provide the first evidence that supports a role for the inflammasome in the pathological inflammation implicated in spontaneous preterm labor with acute histologic chorioamnionitis.

¹ Perinatology Research Branch, Program for Perinatal Research and Obstetrics, Division of Intramural Research, Eunice Kennedy Shriver National Institute of Child Health and Human Development, NICHD/NIH/DHHS, Bethesda, MD, and Detroit, MI, USA

² Department of Obstetrics and Gynecology, Wayne State University School of Medicine, Detroit, MI, USA

³ Department of Immunology and Microbiology, Wayne State University School of Medicine, Detroit, MI, USA

⁴ Department of Obstetrics and Gynecology, University of Michigan, Ann Arbor, MI, USA

⁵ Department of Epidemiology and Biostatistics, Michigan State University, East Lansing, MI, USA

⁶ Center for Molecular Medicine and Genetics, Wayne State University, Detroit, MI, USA

⁷ Systems Biology of Reproduction Lendulet Research Group, Institute of Enzymology, Research Centre for Natural Sciences, Hungarian Academy of Sciences, Budapest, Hungary

⁸ Maternity Private Department, Kutvolgyi Clinical Block, Semmelweis University, Budapest, Hungary

⁹ First Department of Pathology and Experimental Cancer Research, Semmelweis University, Budapest, Hungary

¹⁰ Department of Obstetrics, Gynecology and Reproductive Sciences, Yale University School of Medicine, New Haven, CT, USA

Corresponding Authors:

Roberto Romero, Perinatology Research Branch, NICHD/NIH/DHHS, Wayne State University/Hutzel Women's Hospital, 3990 John R, Box 4, Detroit, MI 48201, USA.

Email: prbchiefstaff@med.wayne.edu

Nardhy Gomez-Lopez, Department of Obstetrics and Gynecology, Wayne State University School of Medicine, Perinatology Research Branch, NICHD/NIH/DHHS, Detroit, MI 48201, USA.

Email: ngomezlo@med.wayne.edu

Keywords

apoptosis-associated speck-like protein containing a CARD (ASC), caspase-1, caspase-4, cytokines, fetal inflammatory response, fever, funisitis, inflammasome assembly, intraamniotic inflammation, microbial invasion of the amniotic cavity, neutrophil, parturition, pregnancy, prematurity, preterm birth, PYD and CARD domain containing (PYCARD) protein, pyroptosis

Introduction

Preterm birth is one of the most common, yet detrimental, obstetrical syndromes¹⁻⁶ and the leading cause of perinatal morbidity and mortality worldwide.⁷⁻¹⁰ Approximately 70% of all preterm births are preceded by spontaneous preterm labor,^{1,5,11-13} a syndrome of multiple pathological processes.¹⁴ Of all the putative causes associated with spontaneous preterm labor, only intraamniotic inflammation/infection has been causally linked to preterm birth.¹⁵⁻³⁸ Intraamniotic inflammation/infection generally results in acute histologic chorioamnionitis;³⁹⁻⁴⁸ thus, this placental lesion is strongly associated with preterm labor and birth.^{40,49-53}

Acute histologic chorioamnionitis can also occur in the setting of sterile intraamniotic inflammation,⁵⁴⁻⁵⁸ an inflammatory process in which microorganisms cannot be detected using both cultivation and molecular microbiology techniques.⁵⁴⁻⁶³ Sterile inflammation is induced by danger signals, termed damage-associated molecular patterns (DAMPs)^{64,65} or alarmins,⁶⁶ derived from necrotic cells or cellular stress.⁶⁷ Therefore, acute histologic chorioamnionitis is evidence of intraamniotic inflammation regardless of the presence of infection.⁶⁸

Acute histologic chorioamnionitis is defined by the infiltration of neutrophils and monocytes/macrophages into the chorioamniotic membranes,^{45,48,68-72} which is mediated by a gradient of potent chemokines, including interleukin (IL)-8,^{68,73,74} C-X-C motif chemokine ligand 6 (CXCL6),^{68,75} and C-C motif chemokine ligand 2 (CCL2)⁷⁶ (also known as monocyte chemoattractant protein or MCP-1). This pathological activation of the innate immune system is observed in spontaneous preterm labor and includes high concentrations of pro-inflammatory cytokines, such as IL-1 α , IL-1 β , tumor necrosis factor α , and IL-6 in the amniotic fluid,⁷⁷⁻⁸⁹ decidua,^{90,91} and umbilical cord blood.⁹²⁻⁹⁴ Elevated concentrations of these cytokines are linked to adverse neonatal outcomes.^{80,82,83,92,95-111} Therefore, the study herein focuses on the mechanisms implicated in the pathophysiology of acute histologic chorioamnionitis in spontaneous preterm labor.

The inflammasome is implicated in physiological¹¹²⁻¹¹⁴ and pathological inflammation (ie, acute histologic chorioamnionitis¹¹⁵) during human parturition at term; however, its role in spontaneous preterm labor is unknown. Inflammasomes are cytoplasmic multiprotein complexes that promote an inflammatory response through the release of the mature forms of IL-1 β and IL-18.¹¹⁶⁻¹⁵⁰ The inflammasome complex contains: (1) a pattern recognition receptor (PRR or sensor molecule), (2) the adaptor protein ASC (apoptosis-associated speck-like protein containing a CARD), and (3) pro-caspase-1 (pro-CASP-1).¹¹⁶⁻¹⁵² Inflammasome activation prompts the release of active CASP-1 which, in turn, can participate in the processing of mature IL-1 β and IL-18.¹⁵³⁻¹⁶³ These events induce a

pro-inflammatory programmed cell death termed pyroptosis.¹⁶⁴⁻¹⁶⁶ In addition, active CASP-4 participates in the noncanonical activation of the inflammasome by activating CASP-1^{149,167-171}, which can lead to pyroptosis and the release of alarmins (eg, high mobility group box-1 or HMGB1) in a CASP-1-independent manner.¹⁷²

Herein, we propose that the inflammasome is implicated in the pathological inflammation (acute histologic chorioamnionitis) associated with spontaneous preterm labor. Such a hypothesis is supported by the fact that amniotic fluid concentrations of CASP-1,¹¹³ IL-1 β ,⁷⁸ and IL-18¹⁷³ are greater in women who undergo spontaneous preterm labor with intraamniotic infection/inflammation than in those without this clinical condition. The aims of this study were to determine whether the chorioamniotic membranes from women in spontaneous preterm labor with acute histologic chorioamnionitis: (1) express major inflammasome components; (2) express CASP-1 and CASP-4 as well as their active forms; (3) exhibit ASC/CASP-1 complex formation; and (4) release the mature forms of IL-1 β and IL-18.

Materials and Methods

Human Participants, Clinical Specimens, and Definitions

In order to conduct this case-control study, chorioamniotic membrane samples from women who underwent spontaneous preterm labor with (PTL-ACA) or without (PTL) acute histologic chorioamnionitis were collected from the Bank of Biological Specimens of the Detroit Medical Center, Wayne State University, and the Perinatology Research Branch (Detroit, Michigan), an intramural program of the Eunice Kennedy Shriver National Institute of Child Health and Human Development, National Institutes of Health, US Department of Health and Human Services. The Institutional Review Boards of these institutions approved the collection and use of biological materials for research purposes. Participants provided written informed consent and samples were collected within 0.5 hour after delivery. Table 1 includes the demographic and clinical characteristics of the study population. Multiparous women or women with neonates having congenital or chromosomal abnormalities were excluded. Preterm labor was diagnosed by the presence of regular uterine contractions (at least 3 in 30 minutes) and documented cervical changes in patients with a gestational age between 20 and 36 6/7 weeks. Preterm delivery was defined as birth prior to week 37 of gestation.

Placental Histopathological Examinations

Five- μ m-thick sections of formalin-fixed, paraffin-embedded tissue specimens were cut and mounted on SuperFrost Plus

Table 1. Demographic and Clinical Characteristics of the Study Groups.

	PTL (n = 33)	PTL-ACA (n = 37)	P Value
Maternal age, years, median (IQR) ^a	24.5 (19.8-32.3)	26 (21-31.3)	NS
Race, n (%) ^b			NS
African American	24 (72.7)	30 (81.1)	
Caucasian	4 (12.1)	5 (13.5)	
Other	5 (15.2)	2 (5.4)	
Maternal weight, kg, median (IQR) ^a	65.5 (54-75.3)	69.5 (54-85)	NS
Body mass index, kg/m ² , median (IQR) ^a	24.6 (20.6-29)	24.4 (20.2-32.9)	NS
Primiparity, n (%) ^b	5 (15.2)	5 (13.5)	NS
Gestational age at delivery, weeks, median (IQR) ^a	31.7 (30-33)	31.8 (30.3-32.9)	NS
Birth weight, g, median (IQR) ^a	1571.5 (1193.8-1928.8)	1560 (1218.8-1906.3)	NS
Cesarean section, n (%) ^b	8 (24.2)	7 (18.9)	NS
Acute histologic chorioamnionitis, n (%) ^b	0 (0)	37 (100)	<.0001

Abbreviations: PTL, preterm labor without acute histologic chorioamnionitis; PTL-ACA, preterm labor with acute histologic chorioamnionitis; IQR, interquartile range; NS, non-significant.

^aMann-Whitney *U* test.

^bFisher's exact test.

microscope slides (Erie Scientific LLC, Portsmouth, New Hampshire). In each case, several tissue sections of the chorioamniotic membranes, umbilical cord, and placental disk were examined. After deparaffinization, slides were rehydrated, stained with hematoxylin–eosin, and evaluated by pathologists who were blinded to the clinical outcome, according to published criteria.^{68,69} The diagnosis of acute histologic chorioamnionitis was made when the infiltration of neutrophils into the chorionic trophoblast layer or chorioamniotic connective tissue was observed.^{68,69}

RNA Isolation, cDNA Generation, and Quantitative Reverse Transcription Polymerase Chain Reaction Analysis

Total RNA was extracted from snap-frozen chorioamniotic membrane samples (PTL, n = 33 and PTL-ACA, n = 37) using TRIzol (Invitrogen, Life Technologies Corporation, Grand Island, New York) and Qiagen RNeasy kits (Qiagen, Gaithersburg, Maryland). The purity, concentration, and integrity of the RNA were assessed using the NanoDrop 1000 spectrophotometer (Thermo Scientific, Wilmington, Delaware, USA) and the Bioanalyzer 2100 (Agilent Technologies, Wilmington, Delaware). cDNA was generated using the SuperScript III First-Strand Synthesis System (Invitrogen) and oligo(dT)20 primers (Invitrogen). Gene expression profiling was performed on the BioMark System for high-throughput quantitative reverse transcription polymerase chain reaction (Fluidigm, San Francisco, California) and the ABI 7500 FAST Real-Time PCR System (Applied Biosystems, Life Technologies Corporation, Foster City, California) with TaqMan gene expression assays (Applied Biosystems) listed in Supplementary Table 1.

Chorioamniotic Membrane Tissue Lysates

Tissue lysates were prepared by homogenizing snap-frozen chorioamniotic membranes (PTL and PTL-ACA, n = 10 each)

in 2 mL of 1X phosphate-buffered saline (PBS; Invitrogen) containing a complete protease inhibitor cocktail (Cat. No. 11697498001; Roche Applied Science, Mannheim, Germany). Next, lysates were centrifuged at 15700×g for 5 minutes at 4°C, and the supernatant was collected and stored at –80°C. Prior to enzyme-linked immunosorbent assay (ELISA) or immunoblotting, total protein determination was determined using the Quick Start Bradford Protein Assay Kit (Bio-Rad, Hercules, California).

Enzyme-Linked Immunosorbent Assays

Protein concentrations of NLR family pyrin domain-containing protein (NLRP1), NLRP3, absent in melanoma 2 (AIM2), nucleotide-binding oligomerization domain (NOD) 2 protein, CASP-1, CASP-4, IL-18, pro-IL-1β, and mature IL-1β were determined in chorioamniotic membrane tissue lysates by immunoassays (NLRP1, NLRP3, and NOD2 ELISA kits from Cusabio, Wuhan, Hubei, P.R. China; AIM2, CASP-1, and CASP-4 ELISA kits from Cloud Clone, Houston, Texas; pro-IL-1β and IL-1β ELISA kits from R&D Systems, Minneapolis, Minnesota; and IL-18 ELISA kits from MBL International Corporation, Woburn, Massachusetts), as previously described.¹¹⁴ The sensitivities of the assays were <4.67 pg/mL for NLRP1, <0.039 ng/mL for NLRP3, <0.056 ng/mL for AIM2, <6.25 pg/mL for NOD2, <0.112 ng/mL for CASP-1, <0.053 ng/mL for CASP-4, 3.3 pg/mL for pro-IL-1β, <1 pg/mL for mature IL-1β, and <12.5 pg/mL for IL-18. The IL-1β ELISA kit measured about 10% of the pro-IL-1β. The immunoassays for NLR family CARD domain-containing protein 4 (NLRC4) and NOD1 did not meet our criteria for validation; instead, immunoblotting was performed.

Immunohistochemistry

Tissue sections (5-μm thick) were prepared from the chorioamniotic membranes (PTL and PTL-ACA, n = 10 each).

Immunohistochemistry for NLRP1, NLRP3, NLRC4, AIM2, NOD1, NOD2, CASP-1, CASP-4, IL-1 β , and IL-18 was performed, as previously described.¹¹⁴ Supplementary Table 2 includes the utilized primary antibodies and immunostaining conditions. Quantification of the intensity was performed using a PerkinElmer Panoramic MIDI slide scanner (PerkinElmer, Waltham, Massachusetts).

Immunoblotting

The protein quantity of NLRC4 and NOD1, as well as the active/mature forms of CASP-1, CASP-4, and IL-18, was determined by immunoblotting. Tissue lysates (50 μ g per well) were subjected to 4% to 12% sodium dodecyl sulphate-polyacrylamide gel electrophoresis (Invitrogen). Separated proteins were then transferred onto nitrocellulose membranes (Bio-Rad). Next, membranes were submerged in blocking solution (5% nonfat dry milk in Tris-buffered saline containing 0.1% Tween-20, Bio-Rad or StartingBlock T20 Block Buffer, ThermoFisher Scientific, Inc, Rockford, Illinois) and probed overnight at 4°C with the following human antibodies: mouse anti-NLRC4 antibody (BioLegend, San Diego, California), rabbit anti-NOD1 polyclonal antibody (Enzo Life Sciences, Farmingdale, New York¹⁷⁴), mouse anti-CASP-1 monoclonal antibody (R&D Systems), rabbit anti-CASP-4 polyclonal antibody (Abcam, Cambridge, Massachusetts), or rabbit anti-IL-18 polyclonal antibody (Santa Cruz Biotechnology, Dallas, Texas). A horseradish peroxidase-conjugated anti-mouse or anti-rabbit immunoglobulin G (IgG; Cell Signaling, Boston, Massachusetts) was used as a secondary antibody. Chemiluminescence signals were detected with ChemiGlow West Reagents (Protein Simple, Santa Clara, California), and images were acquired using the FUJIFILM LAS-4000 Imaging System (FUJIFILM North America Corporation, Valhalla, New York). Finally, nitrocellulose membranes were then stripped with Restore Plus Western Blot Stripping Buffer (Pierce Biotechnology, ThermoFisher Scientific Inc) for 15 minutes, washed with 1X PBS, blocked, and reprobed for 1 hour at room temperature with a mouse anti-beta-actin (ACTB) monoclonal antibody (Sigma-Aldrich). Chemiluminescence signals were again detected with ChemiGlow West Reagents, and images were acquired using the FUJIFILM LAS-4000 Imaging System.

In Situ Proximity Ligation Assay

ASC/CASP-1 complex formation was detected by identifying protein interactions between ASC and CASP-1 using a Duolink in situ proximity ligation assay kit (Olink Bioscience, Uppsala, Sweden), following the manufacturer's instructions. Briefly, chorioamniotic membrane tissues (PTL and PTL-ACA, $n = 7$ each) were frozen in Tissue-Plus O.C.T. compound (Fisher HealthCare, Houston, Texas) immediately after collection. Cryogenic sections were cut to 10 μ m and placed on glass microscope slides (Fisherbrand Superfrost Plus

slides; Thermo Scientific, Waltham, Massachusetts). The sections were fixed using 4% paraformaldehyde (Electron Microscopy Sciences, Hatfield, Pennsylvania) for 20 minutes at room temperature, rinsed with 1X PBS, and permeabilized using 0.25% Triton X-100 (Promega, Madison, Wisconsin) for 5 minutes at room temperature. Prior to staining, nonspecific antibody interactions were blocked using serum-free protein blocker (Cat#X09090; DAKO North America, Carpinteria, California) for 30 minutes at room temperature. The sections were then stained at 4°C overnight with the following antibodies: rabbit anti-human ASC (Cat#AG-25B-0006-C100; Adipogen, San Diego, California) and mouse anti-human CASP-1 (Cat#MAB6251, clone 661228; R&D Systems, Minneapolis, Minnesota). Rabbit IgG and mouse IgG2A were used as negative controls, respectively. Following staining, slides were briefly washed with 1X Wash Buffer A from the Duolink kit and incubated with the provided proximity ligation assay probes for 1 hour at 37°C, followed by a second wash with Wash Buffer A. The slides were then incubated with Duolink ligase solution for 30 minutes at 37°C, washed with Wash Buffer A, and incubated for 100 minutes with Duolink polymerase solution. The slides were washed with 1X Wash Buffer B and mounted with Duolink mounting media with DAPI (4',6-diamidino-2-phenylindole). Immunofluorescence was visualized using an Olympus BX60 fluorescence microscope (Olympus, Tokyo, Japan) at 400 \times magnification. Images were acquired using an Olympus DP71 camera and DP Controller software (Olympus). Semi-quantification was performed using the Duolink image analysis software. Images and a video were acquired using a Zeiss LSM 800 laser scanning confocal microscope (Carl Zeiss Microscopy, Jena, Germany) at the Microscopy, Imaging, and Cytometry Resources Core at Wayne State University School of Medicine (<http://micr.med.wayne.edu/>). ASC/CASP-1 complex formation was calculated by dividing the number of signals over the area of the tissue, which was expressed as pixels.

Statistical Analyses

The SPSS version 19.0 software (SPSS Inc, Chicago, Illinois) was used to analyze demographic and clinical data. Comparisons between the 2 groups (PTL vs PTL-ACA) were performed using the Fisher's exact test for proportions as well as the Mann-Whitney U test for nonnormally distributed continuous variables. Gene expressions relative to *ACTB/GAPDH/RPLP0* were calculated as $-\Delta Ct$ values, where ΔCt ($\Delta Ct = Ct_{\text{target}} - Ct_{\text{reference}}$) was computed for each sample after averaging the Ct values over the technical replicates. Group means of gene expression were then compared using t tests from an analysis of variance linear model and the resulting P values were adjusted using the Benjamini-Hochberg procedure. Spearman correlations were used to examine the relationship between inflammasome components and products. An adjusted P value of $\leq .05$ was considered statistically significant.

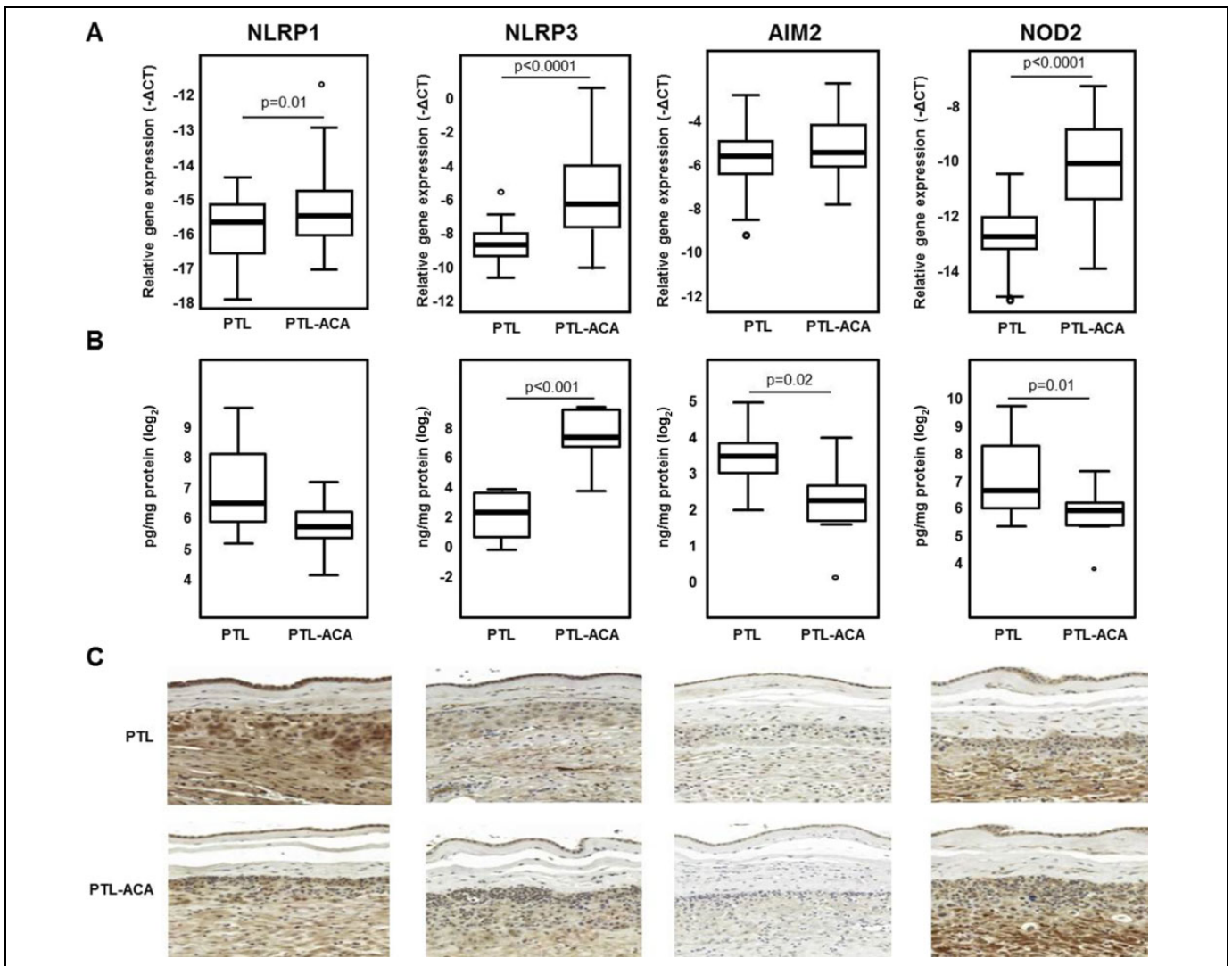


Figure 1. Inflammation components and NOD2 protein in the chorioamniotic membranes. **A**, mRNA abundance of inflammasome components and NOD2 protein in the chorioamniotic membranes from women in spontaneous preterm labor with (PTL-ACA, $n = 37$) or without (PTL, $n = 33$) acute histologic chorioamnionitis. Relative gene expressions are presented as $-\Delta Ct$ values. *T* tests from an analysis of variance (ANOVA) linear model and the resulting *P* values were adjusted using the Benjamini-Hochberg procedure. **B**, Protein concentrations of inflammasome components and NOD2 in chorioamniotic membrane tissue lysates ($n = 10$ each). Mann-Whitney *U* tests. **C**, Representative immunostainings for inflammasome components and NOD2 in the chorioamniotic membranes ($n = 10$ each), 200 \times magnification. Circles denote outlier values. mRNA indicates messenger RNA; NOD, nucleotide-binding oligomerization domain; PTL, preterm labor without acute histologic chorioamnionitis; PTL-ACA, preterm labor with acute histologic chorioamnionitis.

Results

mRNA Abundance and Protein Expression of Inflammasome Components and NOD Proteins in the Chorioamniotic Membranes in Spontaneous Preterm Labor with and without Acute Histologic Chorioamnionitis

First, the expression of major inflammasome components (NLRP1, NLRP3, AIM2, and NLRC4) and NOD proteins (NOD1 and NOD2) was determined in the chorioamniotic membranes from women who had undergone spontaneous preterm labor. The chorioamniotic membranes from women who

had undergone spontaneous preterm labor with and without acute histologic chorioamnionitis expressed all of the inflammasome components. The mRNA abundance of NLRP1, NLRP3, NLRC4, and NOD2 was higher in the chorioamniotic membranes from women who underwent spontaneous preterm labor with acute histologic chorioamnionitis than in those without this placental lesion (Figures 1A and 2A). The protein concentrations of NLRP3 were greater in the chorioamniotic membranes from women who underwent spontaneous preterm labor with acute histologic chorioamnionitis than in those without this placental lesion (Figure 1B). Whereas the protein concentrations of AIM2 and NOD2 were lower in the chorioamniotic membranes from women who underwent spontaneous

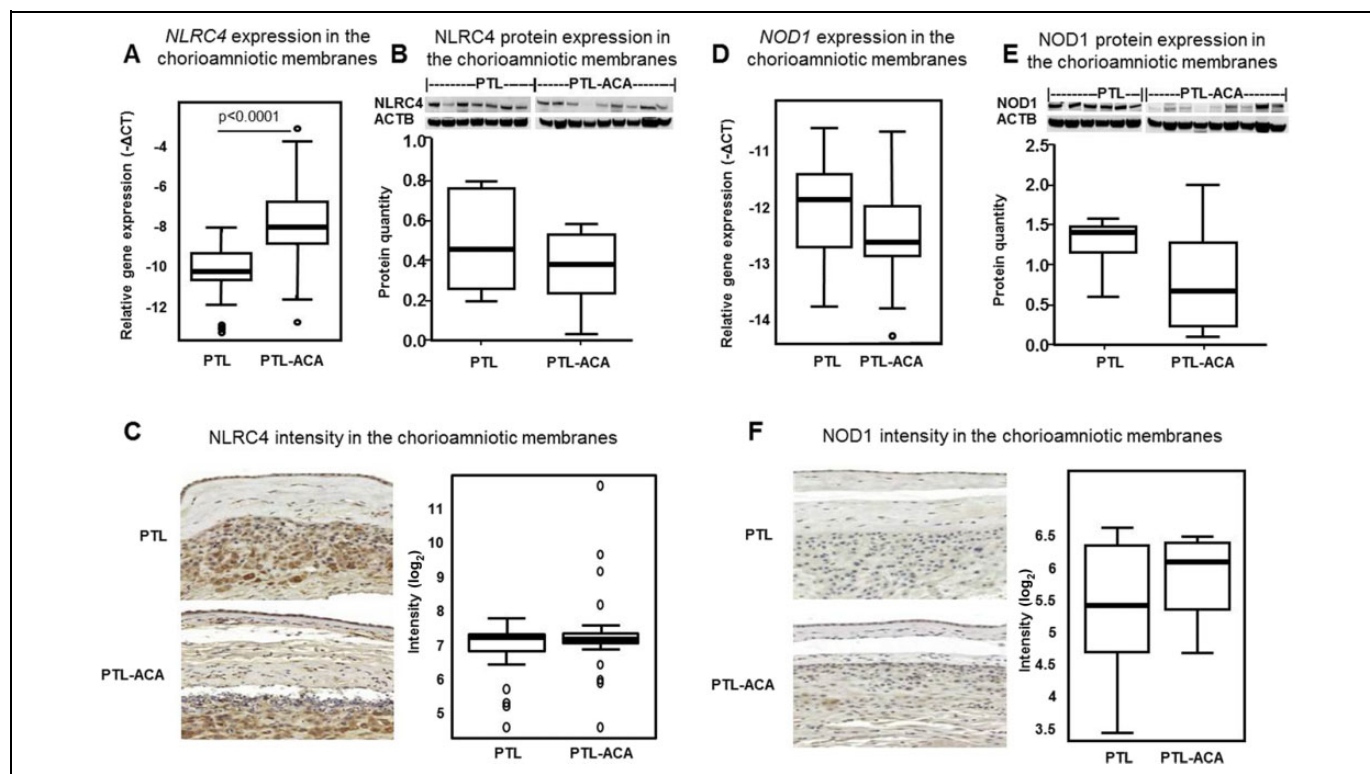


Figure 2. NLRC4 and NOD1 in the chorioamniotic membranes. (A and D) mRNA abundance of *NLRC4* and *NOD1* in the chorioamniotic membranes from women in spontaneous preterm labor with (PTL-ACA, $n = 37$) or without (PTL, $n = 33$) acute histologic chorioamnionitis. Relative gene expressions are presented as $-\Delta\text{Ct}$ values. T tests from an analysis of variance (ANOVA) linear model and the resulting P values were adjusted using the Benjamini-Hochberg procedure. (B and E) Protein quantity of NLRC4 and NOD1 in chorioamniotic membrane tissue lysates ($n = 6-9$ each). Mann-Whitney U tests. (C and F) Intensity of the immunostainings for NLRC4 and NOD1 in the chorioamniotic membranes ($n = 10$ each) and representative immunostainings, $200\times$ magnifications. Mann-Whitney U tests. Circles denote outlier values. mRNA indicates messenger RNA; NLRC4, NLR family CARD domain-containing protein 4; NOD, nucleotide-binding oligomerization domain; PTL, preterm labor without acute histologic chorioamnionitis; PTL-ACA, preterm labor with acute histologic chorioamnionitis.

preterm labor with acute histologic chorioamnionitis than in those without this placental lesion (Figure 1B). The protein concentrations of NLRP1, NLRC4, and NOD1 were similar between these 2 groups (Figures 1B, 2B and E).

Immunohistochemistry analysis revealed that all of the inflammasome components and NOD proteins were expressed in the chorioamniotic membranes from women who had undergone spontaneous preterm labor with and without acute histologic chorioamnionitis. The NLRP1, NLRP3, NLRC4, and NOD2 proteins showed strong immunoreactivity in the chorionic trophoblast cells, decidual stromal cells, and amniotic mesodermal and epithelial cells (Figures 1C and 2C). However, AIM2 and NOD1 showed weak immunoreactivity in the chorionic trophoblast cells, decidual stromal cells, and amniotic mesodermal and epithelial cells (Figures 1C and 2F).

The combined increase in the mRNA abundance and protein expression of NLRP3 in the chorioamniotic membranes from women who underwent spontaneous preterm labor with acute histologic chorioamnionitis suggests that the inflammasome may participate in the pathological activation of the innate immune system, leading to preterm labor in the setting of intraamniotic inflammation.

Activation of CASP-1 and CASP-4 in the Chorioamniotic Membranes in Spontaneous Preterm Labor with Acute Histologic Chorioamnionitis

Next, we examined whether the increased concentration of NLRP3 was linked to the activation of CASP-1 and CASP-4 in the chorioamniotic membranes from women who had undergone spontaneous preterm labor with acute histologic chorioamnionitis. The mRNA abundance of *CASP1* and *CASP4* was greater in the chorioamniotic membranes from women who underwent spontaneous preterm labor with acute histologic chorioamnionitis than in those without this placental lesion (Figure 3A). Although the protein concentrations of CASP-1 and CASP-4 were not significantly different between the 2 groups (Figure 3B), semiquantitative analysis of immunostaining revealed that CASP-1 was increased in the chorioamniotic membranes from women who underwent spontaneous preterm labor with acute histologic chorioamnionitis (Figure 3C). Also, the protein quantities of one of the active forms of CASP-1 (p10) and the active form of CASP-4 (p20) were increased in the chorioamniotic membranes from women who had undergone spontaneous preterm labor with acute histologic

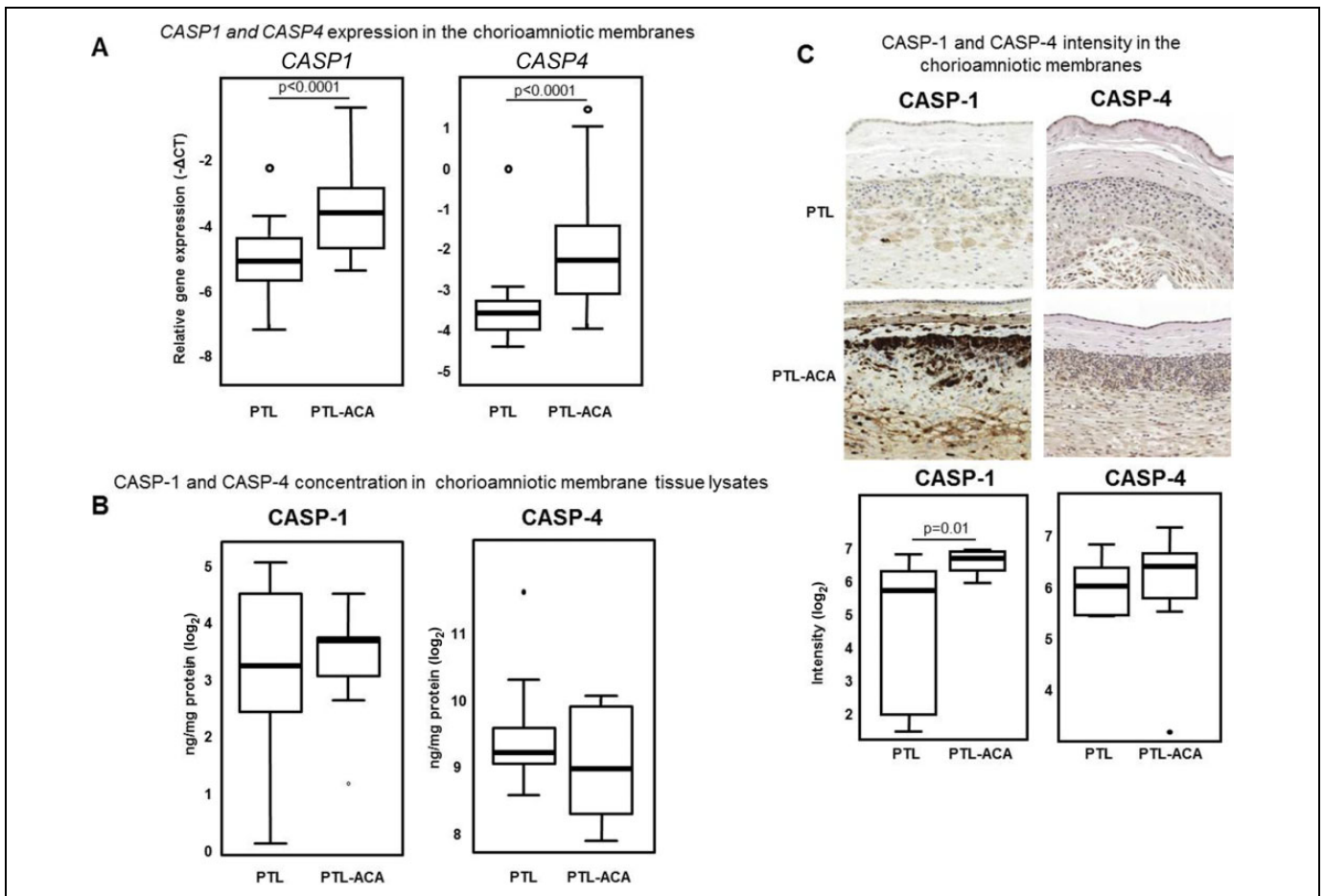


Figure 3. mRNA and protein expression of inflammatory caspases in the chorioamniotic membranes. **A**, mRNA abundance of caspase (*CASP1*) and *CASP4* in the chorioamniotic membranes from women in spontaneous preterm labor with (PTL-ACA, $n = 37$) or without (PTL, $n = 33$) acute histologic chorioamnionitis. Relative gene expressions are presented as $-\Delta C_t$ values. T tests from an analysis of variance (ANOVA) linear model and the resulting P values were adjusted using the Benjamini-Hochberg procedure. **B**, Protein concentrations of *CASP-1* and *CASP-4* in the chorioamniotic membrane tissue lysates ($n = 10$ each). Mann-Whitney U tests. **C**, Intensity of the immunostainings for *CASP-1* and *CASP-4* in the chorioamniotic membranes ($n = 10$ each) and representative immunostainings, $200\times$ magnifications. Mann-Whitney U tests. Circles denote outlier values. mRNA indicates messenger RNA; PTL, preterm labor without acute histologic chorioamnionitis; PTL-ACA, preterm labor with acute histologic chorioamnionitis.

chorioamnionitis (Figure 4A, D, E, and G). In contrast, pro-CASP-1 was reduced in the chorioamniotic membranes from women who had undergone spontaneous preterm labor with acute histologic chorioamnionitis (Figure 4B). The active form of *CASP-1* (p20) in the chorioamniotic membranes from women who had undergone spontaneous preterm labor with acute histologic chorioamnionitis seemed to be lower than in those without this placental lesion; yet, this reduction did not reach statistical significance ($P = .07$, Figure 4C). The quantity of the pro-CASP-4 was not different between these 2 groups (Figure 4F). Altogether, these findings provide evidence that there is activation of *CASP-1* in the chorioamniotic membranes, which is likely mediated by the inflammasome and active *CASP-4* during spontaneous preterm labor with acute histologic chorioamnionitis.

Increased mRNA Abundance and Protein Expression of *IL-1 β* in the Chorioamniotic Membranes in Spontaneous Preterm Labor with Acute Histologic Chorioamnionitis

Active forms of *CASP-1* can convert pro-*IL-1 β* into its mature form.^{154-156,175,176} Active *CASP-4* can also induce the non-canonical activation of *IL-1 β* .^{171,177-181} Hence, we determined whether the activation of *CASP-1* and *CASP-4* was correlated with the abundance of the mature form of *IL-1 β* in the chorioamniotic membranes from women who had undergone spontaneous preterm labor with acute histologic chorioamnionitis. The mRNA abundance of *IL1B* in the chorioamniotic membranes from women who underwent spontaneous preterm labor with acute histologic chorioamnionitis was increased compared to those without this placental lesion (Figure 5A). The

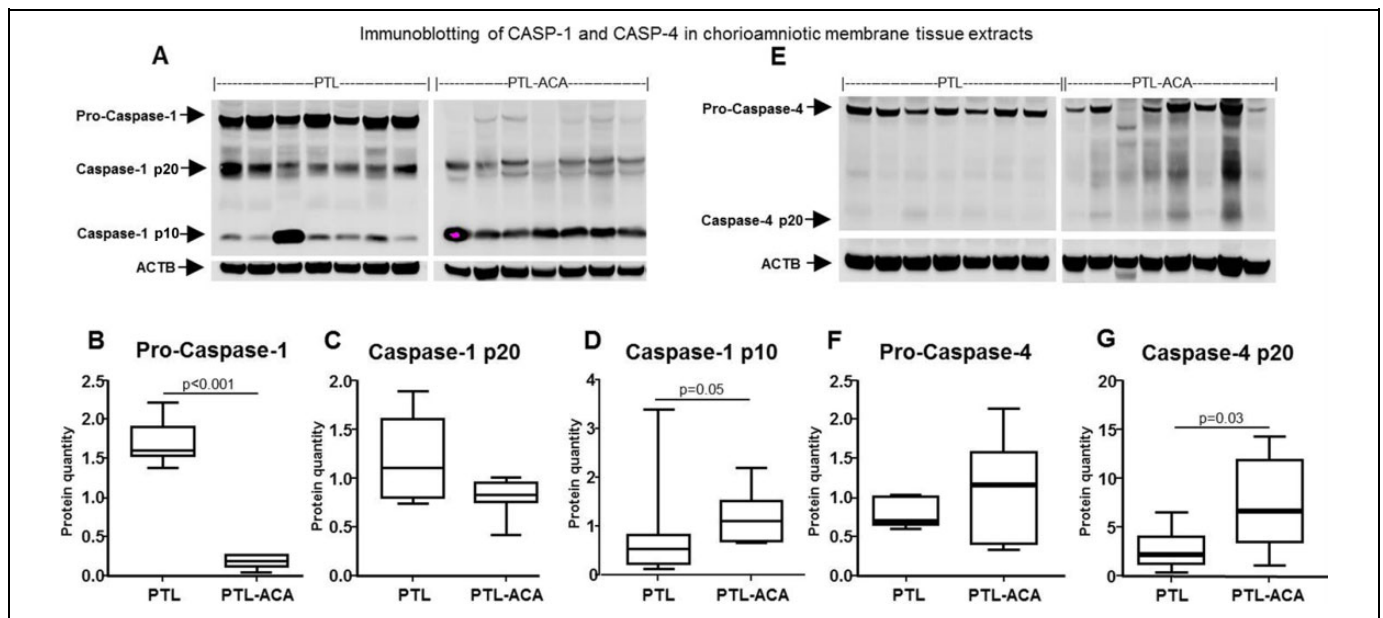


Figure 4. Inflammatory caspases in the chorioamniotic membranes. Immunoblotting of caspase (CASP)-1 (A) in the chorioamniotic membranes from women in spontaneous preterm labor with (PTL-ACA, $n = 7$) or without (PTL, $n = 7$) acute histologic chorioamnionitis. Quantification of the zymogen (B) and its active forms (C and D). Immunoblotting of CASP-4 (E) in the chorioamniotic membranes from women in spontaneous preterm labor with (PTL-ACA, $n = 7$) or without (PTL, $n = 7$) acute histologic chorioamnionitis. Quantification of the zymogen (F) and its active form (G). ACTB was used as an internal control and for quantifications. Mann-Whitney U tests; PTL, preterm labor without acute histologic chorioamnionitis; PTL-ACA, preterm labor with acute histologic chorioamnionitis.

concentration of mature IL-1 β was greater in the chorioamniotic membranes from women who had undergone spontaneous preterm labor with acute histologic chorioamnionitis than in those without this placental lesion (Figure 5B). In contrast, the concentration of pro-IL-1 β was reduced in preterm cases with acute histologic chorioamnionitis (Figure 5B). Furthermore, IL-1 β intensity was stronger in the chorioamniotic membranes from women who underwent spontaneous preterm labor with acute histologic chorioamnionitis than in those without this placental lesion (Figure 5C). These data suggest that the active forms of CASP-1 and CASP-4 may be involved in the processing of mature IL-1 β in the chorioamniotic membranes during spontaneous preterm labor with acute histologic chorioamnionitis.

An Increase in the Protein Expression and Mature Form of IL-18 in the Chorioamniotic Membranes in Spontaneous Preterm Labor with Acute Histologic Chorioamnionitis

Active forms of CASP-1 can convert pro-IL-18 into its mature form.¹⁵⁷ Also, CASP-4 plays a role in the activation and release of IL-18 in response to enteric pathogens (eg, *Salmonella typhimurium* and enteropathogenic *Escherichia coli*) through intracellular endotoxin sensing.¹⁷⁹ Next, we examined whether the activation of CASP-1 and CASP-4 was linked to the release of mature IL-18 by the chorioamniotic membranes from women

who underwent spontaneous preterm labor with acute histologic chorioamnionitis. In line with previously published data,¹⁷³ we found that the chorioamniotic membranes from women who had undergone spontaneous preterm labor with acute histologic chorioamnionitis had a greater protein concentration of IL-18 (Figure 6B) and a higher quantity of the mature form of this cytokine (Figure 6D) than those without this placental lesion. No significant differences were observed in the mRNA abundance (Figure 6A) and immunoreactivity (Figure 6C) of IL-18 in the chorioamniotic membranes between these 2 groups. These data demonstrate that the activation of CASP-1 and CASP-4 is associated with an increase of the protein concentration and mature form of IL-18 in the chorioamniotic membranes from women who had undergone spontaneous preterm labor with acute histologic chorioamnionitis.

A subanalysis of the protein data demonstrated positive and significant correlations between (1) active CASP-1 and mature IL-1 β (Spearman $\rho = .58$, $P = .032$, Supplementary Figure 1A); (2) NLRP3 and mature IL-1 β (Spearman $\rho = .76$, $P < .001$, Supplementary Figure 1B); (3) active CASP-1 and NLRP3 (Spearman $\rho = .69$, $P = .008$, Supplementary Figure 1C); (4) mature IL-18 and NLRP3 (Spearman $\rho = .53$, $P = .036$, Supplementary Figure 1D); and (5) active CASP-4 and mature IL-1 β (Spearman $\rho = .61$, $P = .019$, Supplementary Figure 1E). These results suggest that all of these proteins are increased in chorioamniotic membrane samples from women who underwent spontaneous preterm labor with acute histologic chorioamnionitis compared to those without this placental lesion.

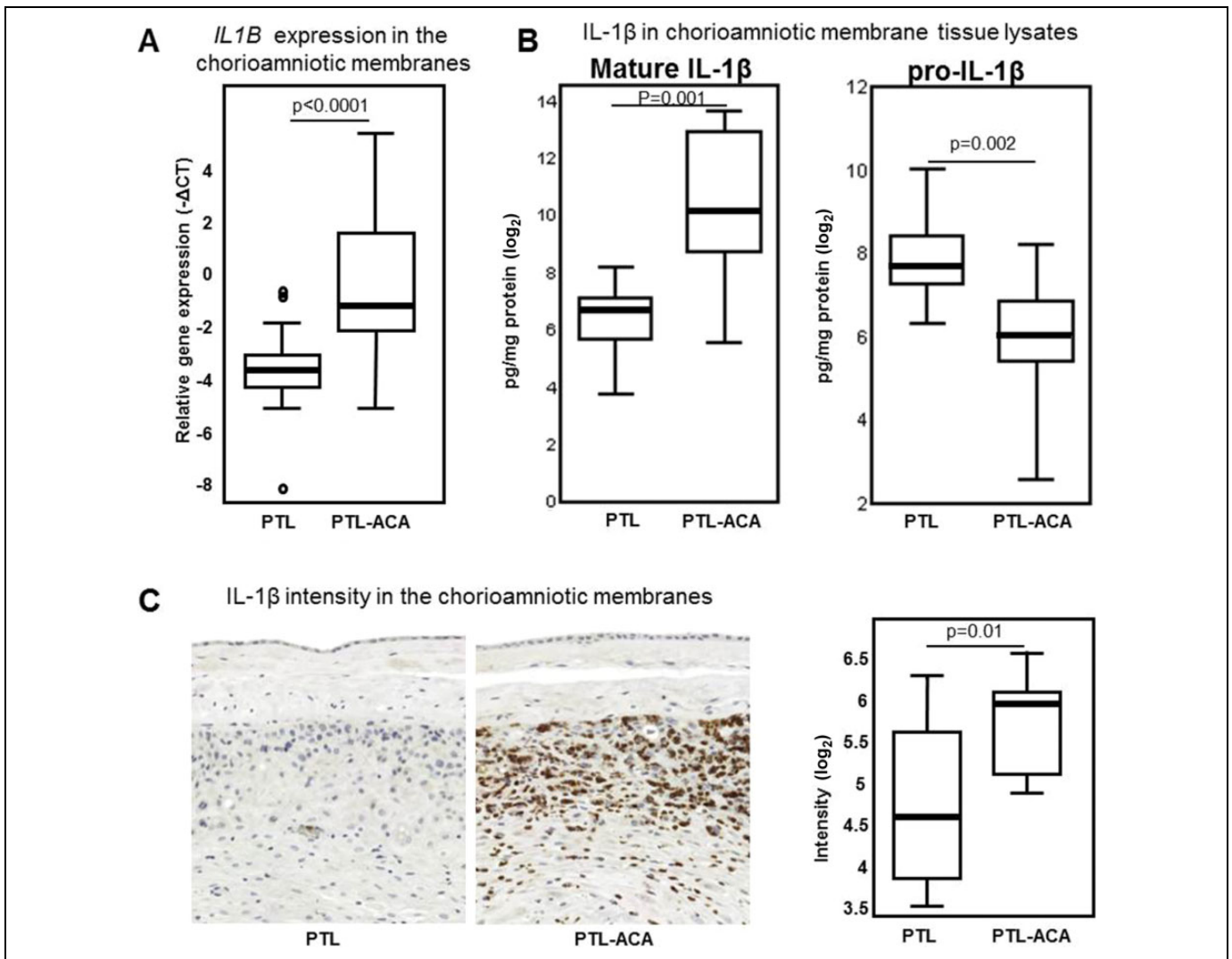


Figure 5. Interleukin (IL)-1 β in the chorioamniotic membranes. A, mRNA abundance of *IL1B* in the chorioamniotic membranes from women in spontaneous preterm labor with (PTL-ACA, $n = 37$) or without (PTL, $n = 33$) acute histologic chorioamnionitis. Relative gene expressions are presented as $-\Delta\text{Ct}$ values. T tests from an analysis of variance (ANOVA) linear model and the resulting P values were adjusted using the Benjamini-Hochberg procedure. Circles denote outlier values. B, Protein concentrations of the pro- and mature form of IL-1 β in the chorioamniotic membrane lysates ($n = 10$ each). Mann-Whitney U tests. C, Intensity of the immunostainings for IL-1 β in the chorioamniotic membranes ($n = 10$ each) and representative immunostainings, 200 \times magnifications. Mann-Whitney U tests. mRNA indicates messenger RNA; PTL, preterm labor without acute histologic chorioamnionitis; PTL-ACA, preterm labor with acute histologic chorioamnionitis.

Increased ASC/CASP-1 Complex Formation in the Chorioamniotic Membranes in Spontaneous Preterm Labor with Acute Histologic Chorioamnionitis

Since there were positive correlations between the NLRP3 protein, the active form of CASP-1, and the mature forms of IL-1 β and IL-18, we next investigated whether there was inflammasome assembly in the chorioamniotic membranes from women who underwent spontaneous preterm labor with acute histologic chorioamnionitis. Inflammasome assembly includes the oligomerization of the NLR protein, adaptor protein ASC, and CASP-1;^{149,182} therefore, we used an in situ proximity ligation assay in order to determine the formation of ASC/CASP-1 complexes. ASC/CASP-1 complexes were

identified in the chorioamniotic membranes from women who underwent spontaneous preterm labor with and without acute histologic chorioamnionitis (Figure 7A and B). However, ASC/CASP-1 complexes were greater in the chorioamniotic membranes from women who had undergone spontaneous preterm labor with acute histologic chorioamnionitis than in those without this placental lesion (Figure 7C). ASC/CASP-1 complexes were not detected in isotype controls (Figure 7D and E). A 3D reconstruction shows that there are ASC/CASP-1 complexes in all of the layers of the chorioamniotic membranes from women who underwent spontaneous preterm labor with acute histologic chorioamnionitis (Supplementary Video 1). These findings provide evidence that there is inflammasome assembly in the chorioamniotic

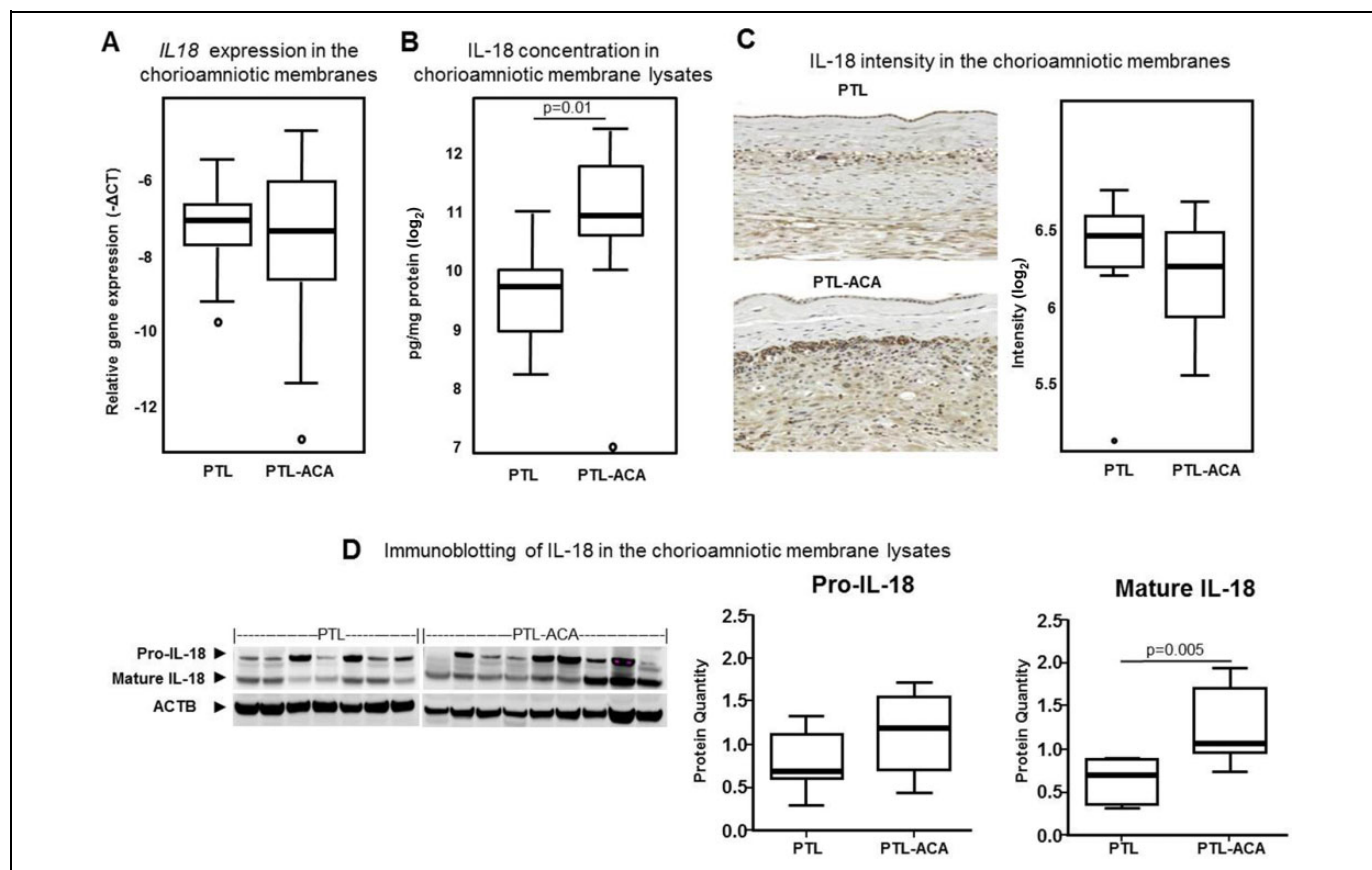


Figure 6. Interleukin (IL)-18 in the chorioamniotic membranes. **A**, mRNA abundance of *IL18* in the chorioamniotic membranes from women in spontaneous preterm labor with (PTL-ACA, $n = 37$) or without (PTL, $n = 33$) acute histologic chorioamnionitis. Relative gene expressions are presented as $-\Delta Ct$ values. T tests from an analysis of variance (ANOVA) linear model and the resulting P values were adjusted using the Benjamini-Hochberg procedure. **B**, Protein concentrations of IL-18 in the chorioamniotic membrane tissue lysates ($n = 10$ each). Mann-Whitney U tests. **C**, Intensity of the immunostainings for IL-18 in the chorioamniotic membranes ($n = 10$ each) and representative immunostainings, $200\times$ magnifications. Mann-Whitney U tests. **D**, Immunoblotting of IL-18 and its mature form in the chorioamniotic membranes and their quantifications ($n = 7-9$ each). ACTB was used as an internal control and for quantifications. Mann-Whitney U tests. Circles denote outlier values. mRNA indicates messenger RNA; PTL, preterm labor without acute histologic chorioamnionitis; PTL-ACA, preterm labor with acute histologic chorioamnionitis.

membranes during spontaneous preterm labor with acute histologic chorioamnionitis.

Discussion

Principal Findings of the Study

When comparing the chorioamniotic membranes from women in spontaneous preterm labor with acute histologic chorioamnionitis to those without this placental lesion, we found that (1) the mRNA expression of *NLRP1*, *NLRP3*, *NLRC4*, and *NOD2* was higher; (2) the *NLRP3* protein was increased; (3) the mRNA and active form of *CASP-1* were greater; (4) the mRNA and active form of *CASP-4* were increased; (5) the mRNA and mature form of IL-1 β were higher; (6) the mature form of IL-18 was elevated; and (7) *ASC/CASP-1* complexes were increased. Altogether, these findings provide the first evidence that supports a role for the inflammasome in the pathological inflammatory process in the chorioamniotic membranes from

women who had undergone spontaneous preterm labor with acute histologic chorioamnionitis.

A role for the inflammasome in the physiological¹¹²⁻¹¹⁴ and pathological^{113,114} inflammatory process of term parturition has been previously reported. Herein, we provided the first evidence that the *NLRP3* inflammasome is involved in the pathological pro-inflammatory process of preterm parturition. The *NLRP3* inflammasome includes the *NLRP3* protein, the adaptor molecule *ASC* with 2 death-fold domains (1 pyrin domain and 1 CARD), and pro-*CASP-1*.^{144,151,183,184} Several stimuli¹⁸⁵⁻¹⁹¹ including crystalline material,^{187,192} necrosis-derived extracellular adenosine triphosphate,¹⁹³ vaccine adjuvants,¹⁹⁴⁻¹⁹⁸ phospholipid cardiolipin and mitochondrial DNA,¹⁹⁹⁻²⁰¹ bacterial toxins,^{193,202,203} and other DAMPs^{189,190} and pathogen-associated molecular patterns (PAMPs)^{120,204-214} can induce the activation of the *NLRP3* inflammasome. The process of activation of this inflammasome includes 2 steps—the priming and the oligomerization or assembly of the multi-protein complex.^{182,215} The first step includes the sensing of

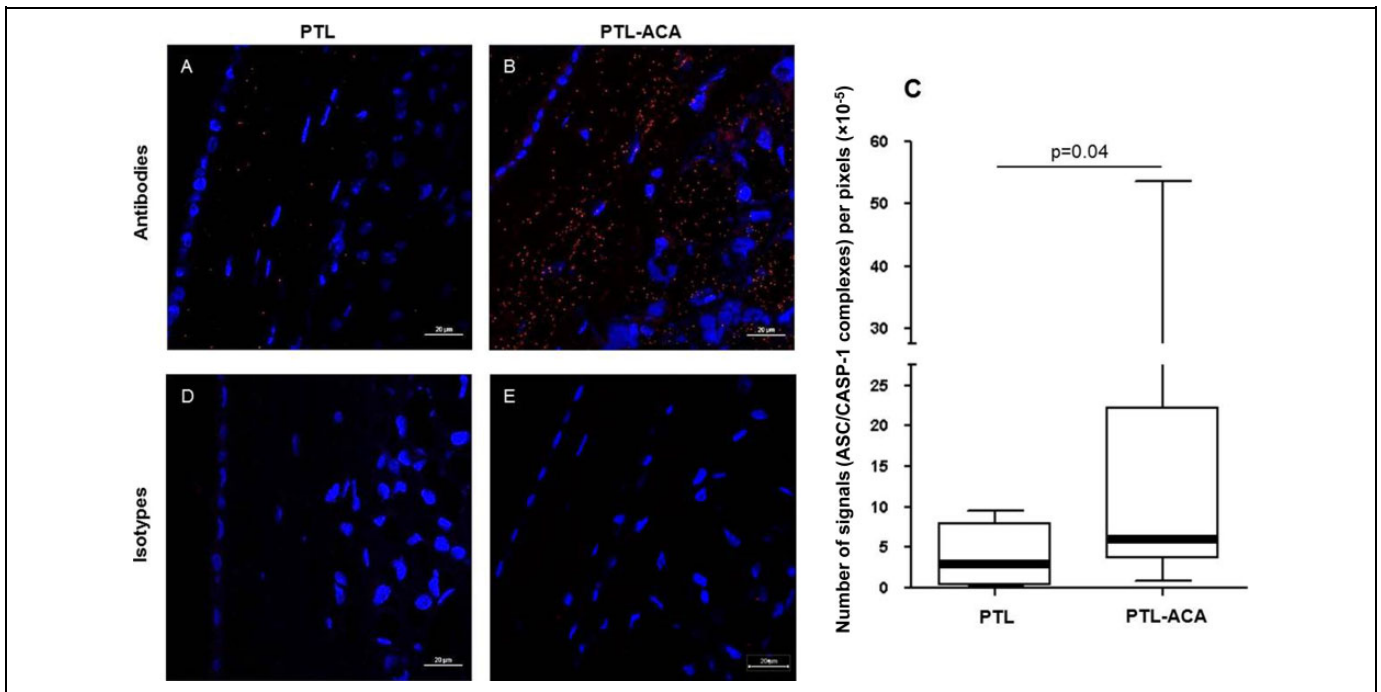


Figure 7. ASC/caspase (CASP)-1 complex formation in the chorioamniotic membranes. In situ proximity ligation assays for ASC and CASP-1 in the chorioamniotic membranes from women in spontaneous preterm labor with (PTL-ACA) or without (PTL) acute histologic chorioamnionitis. (A and B) Representative images of ASC/CASP-1 complexes (red signal) in PTL and PTL-ACA groups. (D and E) Representative images of isotype controls in PTL and PTL-ACA groups. The blue signal is DAPI (nuclei). 400 \times magnifications. C, Semi-quantification of the number of ASC/CASP-1 complexes in the chorioamniotic membranes (PTL and PTL-ACA, $n = 7$ each). ASC/CASP-1 complexes were calculated by dividing the number of signals over the area of the tissue, which was expressed as pixels. Mann-Whitney U tests.

the DAMP and/or PAMP via the PRR which, in turn, induces the activation of the nuclear factor kappa B pathway, resulting in the upregulation of the NLRP3 protein and the expression of pro-IL-1 β .^{182,215,216} The second step permits the oligomerization or assembly of the inflammasome complex, which includes the NLRP3, ASC, and CASP-1 proteins.^{182,215} The current study provides evidence that there is priming and assembly of the NLRP3 inflammasome complex in the chorioamniotic membranes during spontaneous preterm labor with acute histologic chorioamnionitis. It is worth mentioning that there were some ASC/CASP-1 complexes (ie, inflammasome assembly) in the chorioamniotic membranes from women who underwent spontaneous preterm labor without acute chorioamnionitis. These data suggest that the inflammasome is also involved in the process of preterm parturition in the absence of acute histologic chorioamnionitis.

Oligomerization of the inflammasome leads to the recruitment of ASC, which binds and activates pro-CASP-1 via its CARD.^{144,217} In the study herein, we found that the mRNA abundance, immunoreactivity, and the active form of CASP-1 (p10) are increased in the chorioamniotic membranes in spontaneous preterm labor with acute histologic chorioamnionitis. This finding is consistent with previous studies demonstrating that: (1) amniotic fluid CASP-1 concentrations are greater in women who underwent spontaneous preterm labor with intraamniotic infection/inflammation than in those who underwent preterm labor without this clinical condition;¹¹³ and (2)

CASP-1 concentration and the abundance of its mature form are increased in the uteri of mice prior to inflammation-induced preterm birth (mice injected with peptidoglycan and polyinosinic-polycytidylic acid) compared to term controls.²¹⁸ Together, these data suggest that during spontaneous preterm labor with acute histologic chorioamnionitis, the chorioamniotic membranes release abundant quantities of the active form of CASP-1, which is most likely mediated by the inflammasome.

CASP-4 (murine homologue CASP-11) is implicated in the activation of CASP-1 and participates in the non-canonical activation of the inflammasome.^{149,172,213,219} In the current study, we found that the mRNA abundance of CASP-4 and its mature form (p20) were increased in the chorioamniotic membranes from women who underwent spontaneous preterm labor with acute histologic chorioamnionitis. These data indicate that CASP-4 could be mediating the noncanonical activation of the inflammasome in spontaneous preterm labor with acute histologic chorioamnionitis. We suggest that the activation of CASP-4 is also implicated in the induction of preterm parturition in the setting of sterile intraamniotic inflammation. This concept is based on 2 observations—(1) CASP-4 can induce the release of alarmins in a CASP-1-independent manner¹⁷² and (2) the intraamniotic administration of HMGB1 (a classic alarmin²²⁰) can induce preterm labor and birth.²²¹

Following activation, CASP-1 converts inactive pro-IL-1 β into its mature and secreted form.^{155,222-228} IL-1 β induces the expression and release of different mediators implicated in the

process of labor.²²⁹⁻²³⁵ Indeed, the administration of IL-1 β causes preterm birth in mice^{236,237} and monkeys,²³⁸⁻²⁴⁵ confirming an essential role for this cytokine in the pathological process of labor. This effect can be abrogated by the administration of the IL-1 β receptor antagonist.²³⁷ In the study herein, we demonstrated that the chorioamniotic membranes from women in spontaneous preterm labor with acute histologic chorioamnionitis released high amounts of mature IL-1 β , which is most likely mediated by the active forms of CASP-1. This mature form of IL-1 β will then participate in the pathological pro-inflammatory milieu that accompanies the premature process of labor. It is worth mentioning that pro-IL-1 β was reduced in the chorioamniotic membranes from women in spontaneous preterm labor with acute histologic chorioamnionitis compared to those without this placental lesion, which is most likely due to the processing of this zymogen into its mature form.

The active forms of CASP-1^{157-160,163} and CASP-4¹⁷⁹ can also convert pro-IL-18 into its mature form. IL-18 is present in the amniotic fluid, and its concentration is greater in women who underwent spontaneous preterm labor with microbial invasion of the amniotic cavity than in those without this clinical condition.^{173,246} In the present study, the total concentration and mature form of IL-18 was increased in the chorioamniotic membranes from women who underwent spontaneous preterm labor with acute histologic chorioamnionitis. IL-18 is a major interferon γ inducing factor that activates Th-1 responses in T cells and natural killer cells.²⁴⁷⁻²⁵⁴ Therefore, it is likely that IL-18 participates in the cellular pro-inflammatory milieu in the chorioamniotic membranes during spontaneous preterm labor with acute histologic chorioamnionitis.

Conclusion

Herein, we provide the first evidence that supports a role for the NLRP3 inflammasome and CASP-4 in the activation of CASP-1 and the consequent release of mature IL-1 β and IL-18 by the chorioamniotic membranes from women who underwent spontaneous preterm labor with acute histologic chorioamnionitis. These findings provide insight into the mechanisms that are implicated in the pathological pro-inflammatory process of spontaneous preterm labor in acute inflammation of the chorioamniotic membranes.

Acknowledgments

The authors gratefully acknowledge Valeria Garcia-Flores, Derek Miller, Lorri McLuckie, Rona Wang, Yang Jiang, Gaurav Bhatti, and Zhonghui Xu for their contributions to the execution of this study. The authors thank the physicians and nurses from the Center for Advanced Obstetrical Care and Research and the Intrapartum Unit for their help in collecting human samples. The authors also thank staff members of the PRB Clinical Laboratory and the PRB Histology/Pathology Unit for the processing and examination of the pathological sections. Finally, the authors thank Tara Mial for her critical readings of the manuscript.

Declaration of Conflicting Interests

The author(s) declared no potential conflicts of interest with respect to the research, authorship, and/or publication of this article.

Funding

The author(s) disclosed receipt of the following financial support for the research, authorship, and/or publication of this article: This research was supported, in part, by the Perinatology Research Branch, Division of Intramural Research, Eunice Kennedy Shriver National Institute of Child Health and Human Development, National Institutes of Health, US Department of Health and Human Services (NICHD/NIH/DHHS), and, in part, with federal funds from the NICHD/NIH/DHHS under contract no. HHSN275201300006C. This research was also supported by the Wayne State University Perinatal Initiative in Maternal, Perinatal, and Child Health.

Supplementary Material

Supplementary material is available for this article online.

References

- Romero R, Mazor M, Munoz H, Gomez R, Galasso M, Sherer DM. The preterm labor syndrome. *Ann N Y Acad Sci.* 1994;734:414-429.
- Romero R. Prenatal medicine: the child is the father of the man. 1996. *Prenatal Neonatal Med.* 1996;1:8-11.
- Romero R, Espinoza J, Kusanovic JP, et al. The preterm parturition syndrome. *BJOG.* 2006;113(suppl 3):17-42.
- Gotsch F, Romero R, Erez O, et al. The preterm parturition syndrome and its implications for understanding the biology, risk assessment, diagnosis, treatment and prevention of preterm birth. *J Matern Fetal Neonatal Med.* 2009;22(suppl 2):5-23.
- Romero R, Lockwood CJ. Pathogenesis of spontaneous preterm labor. In: Creasy RK, Resnik R, Iams J, eds. *Creasy and Resnik's Maternal-Fetal Medicine: Principles and Practice.* 6th ed. Philadelphia, PA: Elsevier; 2009:521-543.
- Romero R. Prenatal medicine: the child is the father of the man. 1996. *J Matern Fetal Neonatal Med.* 2009;22(8):636-639.
- Muglia LJ, Katz M. The enigma of spontaneous preterm birth. *N Engl J Med.* 2010;362(6):529-535.
- Blencowe H, Cousens S, Oestergaard MZ, et al. National, regional, and worldwide estimates of preterm birth rates in the year 2010 with time trends since 1990 for selected countries: a systematic analysis and implications. *Lancet.* 2012;379(9832):2162-2172.
- Hamilton BE, Hoyert DL, Martin JA, Strobino DM, Guyer B. Annual summary of vital statistics: 2010-2011. *Pediatrics.* 2013;131(3):548-558.
- Liu L, Oza S, Hogan D, et al. Global, regional, and national causes of child mortality in 2000-13, with projections to inform post-2015 priorities: an updated systematic analysis. *Lancet.* 2015;385(9966):430-440.
- Berkowitz GS, Blackmore-Prince C, Lapinski RH, Savitz DA. Risk factors for preterm birth subtypes. *Epidemiology.* 1998;9(3):279-285.

12. Moutquin JM. Classification and heterogeneity of preterm birth. *BJOG*. 2003;110(suppl 20):30-33.
13. Goldenberg RL, Culhane JF, Iams JD, Romero R. Epidemiology and causes of preterm birth. *Lancet*. 2008;371(9606):75-84.
14. Romero R, Dey SK, Fisher SJ. Preterm labor: one syndrome, many causes. *Science*. 2014;345(6198):760-765.
15. Bobitt JR, Ledger WJ. Unrecognized amnionitis and prematurity: a preliminary report. *J Reprod Med*. 1977;19(1):8-12.
16. Bobitt JR, Ledger WJ. Amniotic fluid analysis. Its role in maternal neonatal infection. *Obstet Gynecol*. 1978;51(1):56-62.
17. Miller JM Jr, Pupkin MJ, Hill GB. Bacterial colonization of amniotic fluid from intact fetal membranes. *Am J Obstet Gynecol*. 1980;136(6):796-804.
18. Bobitt JR, Hayslip CC, Damato JD. Amniotic fluid infection as determined by transabdominal amniocentesis in patients with intact membranes in premature labor. *Am J Obstet Gynecol*. 1981;140(8):947-952.
19. Wallace RL, Herrick CN. Amniocentesis in the evaluation of premature labor. *Obstet Gynecol*. 1981;57(4):483-486.
20. Wahbeh CJ, Hill GB, Eden RD, Gall SA. Intra-amniotic bacterial colonization in premature labor. *Am J Obstet Gynecol*. 1984;148(6):739-743.
21. Romero R, Mazor M, Wu YK, et al. Infection in the pathogenesis of preterm labor. *Semin Perinatol*. 1988;12(4):262-279.
22. Romero R, Mazor M. Infection and preterm labor. *Clin Obstet Gynecol*. 1988;31(3):553-584.
23. Romero R, Sirtori M, Oyarzun E, et al. Infection and labor. V. Prevalence, microbiology, and clinical significance of intraamniotic infection in women with preterm labor and intact membranes. *Am J Obstet Gynecol*. 1989;161(2675611): 817-824.
24. Romero R, Avila C, Brekus CA, Morotti R. The role of systemic and intrauterine infection in preterm parturition. *Ann N Y Acad Sci*. 1991;622:355-375.
25. Watts DH, Krohn MA, Hillier SL, Eschenbach DA. The association of occult amniotic fluid infection with gestational age and neonatal outcome among women in preterm labor. *Obstet Gynecol*. 1992;79(3):351-357.
26. Gibbs RS, Romero R, Hillier SL, Eschenbach DA, Sweet RL. A review of premature birth and subclinical infection. *Am J Obstet Gynecol*. 1992;166(5):1515-1528.
27. Gomez R, Romero R, Edwin SS, David C. Pathogenesis of preterm labor and preterm premature rupture of membranes associated with intraamniotic infection. *Infect Dis Clin North Am*. 1997; 11(1):135-176.
28. Romero R, Gomez R, Chaiworapongsa T, Conoscenti G, Kim JC, Kim YM. The role of infection in preterm labour and delivery. *Paediatr Perinat Epidemiol*. 2001;15(suppl 2):41-56.
29. Yoon BH, Romero R, Moon JB, et al. The frequency and clinical significance of intra-amniotic inflammation in patients with a positive cervical fetal fibronectin. *Am J Obstet Gynecol*. 2001; 185(5):1137-1142.
30. Yoon BH, Romero R, Moon JB, et al. Clinical significance of intra-amniotic inflammation in patients with preterm labor and intact membranes. *Am J Obstet Gynecol*. 2001;185(5): 1130-1136.
31. Romero R, Espinoza J, Chaiworapongsa T, Kalache K. Infection and prematurity and the role of preventive strategies. *Semin Neonatol*. 2002;7(4):259-274.
32. Shim SS, Romero R, Hong JS, et al. Clinical significance of intra-amniotic inflammation in patients with preterm premature rupture of membranes. *Am J Obstet Gynecol*. 2004;191(4):1339-1345.
33. Romero R, Gotsch F, Pineles B, Kusanovic JP. Inflammation in pregnancy: its roles in reproductive physiology, obstetrical complications, and fetal injury. *Nutr Rev*. 2007;65(12 pt 2): S194-S202.
34. Lee SE, Romero R, Jung H, Park CW, Park JS, Yoon BH. The intensity of the fetal inflammatory response in intraamniotic inflammation with and without microbial invasion of the amniotic cavity. *Am J Obstet Gynecol*. 2007;197(3):294.e291-e296.
35. Lee SE, Romero R, Park CW, Jun JK, Yoon BH. The frequency and significance of intraamniotic inflammation in patients with cervical insufficiency. *Am J Obstet Gynecol*. 2008;198(6):633.e631-e638.
36. Lee SE, Romero R, Lee SM, Yoon BH. Amniotic fluid volume in intra-amniotic inflammation with and without culture-proven amniotic fluid infection in preterm premature rupture of membranes. *J Perinat Med*. 2010;38(1):39-44.
37. Madan I, Romero R, Kusanovic JP, et al. The frequency and clinical significance of intra-amniotic infection and/or inflammation in women with placenta previa and vaginal bleeding: an unexpected observation. *J Perinat Med*. 2010;38(3):275-279.
38. Kim SM, Romero R, Lee J, et al. The frequency and clinical significance of intra-amniotic inflammation in women with preterm uterine contractility but without cervical change: do the diagnostic criteria for preterm labor need to be changed? *J Matern Fetal Neonatal Med*. 2012;25(8):1212-1221.
39. Blanc WA. Amniotic infection syndrome; pathogenesis, morphology, and significance in circumnata mortality. *Clin Obstet Gynecol*. 1959;2:705-734.
40. Russell P. Inflammatory lesions of the human placenta: clinical significance of acute chorioamnionitis. *Am J Diagn Gynecol Obstet*. 1979;2:127-137.
41. Blanc WA. Pathology of the placenta and cord in ascending and in haematogenous infection. *Ciba Found Symp*. 1979(77):17-38.
42. Hillier SL, Martius J, Krohn M, Kiviat N, Holmes KK, Eschenbach DA. A case-control study of chorioamnionic infection and histologic chorioamnionitis in prematurity. *N Engl J Med*. 1988; 319(15):972-978.
43. Hillier SL, Krohn MA, Kiviat NB, Watts DH, Eschenbach DA. Microbiologic causes and neonatal outcomes associated with chorioamnion infection. *Am J Obstet Gynecol*. 1991;165(4 pt 1):955-961.
44. Romero R, Salafia CM, Athanassiadis AP, et al. The relationship between acute inflammatory lesions of the preterm placenta and amniotic fluid microbiology. *Am J Obstet Gynecol*. 1992;166(5): 1382-1388.
45. Redline RW, Faye-Petersen O, Heller D, Qureshi F, Savell V, Vogler C; Society for Pediatric Pathology, Perinatal Section, Amniotic Fluid Infection Nosology Committee. Amniotic infection syndrome: nosology and reproducibility of placental reaction patterns. *Pediatr Dev Pathol*. 2003;6(5):435-448.

46. Redline RW. Placental inflammation. *Semin Neonatol.* 2004;9(4): 265-274.
47. Fox H, Sebire NJ. Infections and inflammatory lesions of the placenta. *Pathology of the placenta.* 3rd ed. Edinburgh, Scotland: Elsevier Saunders; 2007:303-354.
48. Benirschke K, Burton G, Baergen R. Infectious diseases. *Pathology of the Human Placenta:* Springer Berlin Heidelberg; 2012: 557-655.
49. Guzik DS, Winn K. The association of chorioamnionitis with preterm delivery. *Obstet Gynecol.* 1985;65(1):11-16.
50. van Hoesen KH, Anyaegbunam A, Hochster H, et al. Clinical significance of increasing histologic severity of acute inflammation in the fetal membranes and umbilical cord. *Pediatr Pathol Lab Med.* 1996;16(5):731-744.
51. Srinivas SK, Ma Y, Sammel MD, et al. Placental inflammation and viral infection are implicated in second trimester pregnancy loss. *Am J Obstet Gynecol.* 2006;195(3):797-802.
52. Srinivas SK, Ernst LM, Edlow AG, Elovitz MA. Can placental pathology explain second-trimester pregnancy loss and subsequent pregnancy outcomes? *Am J Obstet Gynecol.* 2008;199(4): 402.e401-405.
53. Taguchi A, Yamashita A, Kawana K, et al. Recent progress in therapeutics for inflammation-associated preterm birth: a review [published online December 1, 2015]. *Reprod Sci.* pii: 1933719115618282.
54. Romero R, Miranda J, Chaiworapongsa T, et al. A novel molecular microbiologic technique for the rapid diagnosis of microbial invasion of the amniotic cavity and intra-amniotic infection in preterm labor with intact membranes. *Am J Reprod Immunol.* 2014;71(4):330-358.
55. Romero R, Miranda J, Chaiworapongsa T, et al. Prevalence and clinical significance of sterile intra-amniotic inflammation in patients with preterm labor and intact membranes. *Am J Reprod Immunol.* 2014;72(5):458-474.
56. Romero R, Miranda J, Chaiworapongsa T, et al. Sterile intra-amniotic inflammation in asymptomatic patients with a sonographic short cervix: prevalence and clinical significance [published online September 24, 2014]. *J Matern Fetal Neonatal Med:* 1-17.
57. Romero R, Miranda J, Chaemsaitong P, et al. Sterile and microbial-associated intra-amniotic inflammation in preterm pre-labor rupture of membranes. *J Matern Fetal Neonatal Med.* 2015; 28(12):1394-1409.
58. Romero R, Miranda J, Kusanovic JP, et al. Clinical chorioamnionitis at term I: microbiology of the amniotic cavity using cultivation and molecular techniques. *J Perinat Med.* 2015;43(1):19-36.
59. Romero R, Chaemsaitong P, Korzeniewski SJ, et al. Clinical chorioamnionitis at term II: the intra-amniotic inflammatory response. *J Perinat Med.* 2016;44(1):5-22.
60. Romero R, Chaemsaitong P, Korzeniewski SJ, et al. Clinical chorioamnionitis at term III: how well do clinical criteria perform in the identification of proven intra-amniotic infection? *J Perinat Med.* 2016;44(1):23-32.
61. Romero R, Chaemsaitong P, Docheva N, et al. Clinical chorioamnionitis at term IV: the maternal plasma cytokine profile. *J Perinat Med.* 2016;44(1):77-98.
62. Romero R, Chaemsaitong P, Docheva N, et al. Clinical chorioamnionitis at term V: umbilical cord plasma cytokine profile in the context of a systemic maternal inflammatory response. *J Perinat Med.* 2016;44(1):53-76.
63. Romero R, Chaemsaitong P, Docheva N, et al. Clinical chorioamnionitis at term VI: acute chorioamnionitis and funisitis according to the presence or absence of microorganisms and inflammation in the amniotic cavity. *J Perinat Med.* 2016; 44(1):33-51.
64. Rubartelli A, Lotze MT. Inside, outside, upside down: damage-associated molecular-pattern molecules (DAMPs) and redox. *Trends Immunol.* 2007;28(10):429-436.
65. Lotze MT, Zeh HJ, Rubartelli A, et al. The grateful dead: damage-associated molecular pattern molecules and reduction/oxidation regulate immunity. *Immunol Rev.* 2007;220:60-81.
66. Oppenheim JJ, Yang D. Alarmins: chemotactic activators of immune responses. *Curr Opin Immunol.* 2005;17(4):359-365.
67. Chen GY, Nunez G. Sterile inflammation: sensing and reacting to damage. *Nat Rev Immunol.* 2010;10(12):826-837.
68. Kim CJ, Romero R, Chaemsaitong P, Chaiyasit N, Yoon BH, Kim YM. Acute chorioamnionitis and funisitis: definition, pathologic features, and clinical significance. *Am J Obstet Gynecol.* 2015;213(suppl 4): S29-S52.
69. Redline RW. Classification of placental lesions. *Am J Obstet Gynecol.* 2015;213(4 Suppl):S21-8.
70. Kim CJ, Romero R, Kusanovic JP, et al. The frequency, clinical significance, and pathological features of chronic chorioamnionitis: a lesion associated with spontaneous preterm birth. *Mod Pathol.* 2010;23(7):1000-1011.
71. Toti P, Arcuri F, Tang Z, et al. Focal increases of fetal macrophages in placentas from pregnancies with histological chorioamnionitis: potential role of fibroblast monocyte chemotactic protein-1. *Am J Reprod Immunol.* 2011;65(5):470-479.
72. Redline RW. Inflammatory response in acute chorioamnionitis. *Semin Fetal Neonatal Med.* 2012;17(1):20-25.
73. Cherouny PH, Pankuch GA, Romero R, et al. Neutrophil attractant/activating peptide-1/interleukin-8: association with histologic chorioamnionitis, preterm delivery, and bioactive amniotic fluid leukoattractants. *Am J Obstet Gynecol.* 1993;169(5): 1299-1303.
74. Kacerovsky M, Drahosova M, Hornychova H, et al. Value of amniotic fluid interleukin-8 for the prediction of histological chorioamnionitis in preterm premature rupture of membranes. *Neuro Endocrinol Lett.* 2009;30(6):733-738.
75. Mittal P, Romero R, Kusanovic JP, et al. CXCL6 (granulocyte chemotactic protein-2): a novel chemokine involved in the innate immune response of the amniotic cavity. *Am J Reprod Immunol.* 2008;60(3):246-257.
76. Esplin MS, Romero R, Chaiworapongsa T, et al. Monocyte chemotactic protein-1 is increased in the amniotic fluid of women who deliver preterm in the presence or absence of intra-amniotic infection. *J Matern Fetal Neonatal Med.* 2005;17(6):365-373.
77. Romero R, Avila C, Santhanam U, Sehgal PB. Amniotic fluid interleukin 6 in preterm labor. Association with infection. *J Clin Invest.* 1990;85(5):1392-1400.

78. Romero R, Mazor M, Brandt F, et al. Interleukin-1 alpha and interleukin-1 beta in preterm and term human parturition. *Am J Reprod Immunol*. 1992;27(3-4):117-123.
79. Romero R, Yoon BH, Kenney JS, Gomez R, Allison AC, Sehgal PB. Amniotic fluid interleukin-6 determinations are of diagnostic and prognostic value in preterm labor. *Am J Reprod Immunol*. 1993;30(2-3):167-183.
80. Hillier SL, Witkin SS, Krohn MA, Watts DH, Kiviat NB, Eschenbach DA. The relationship of amniotic fluid cytokines and preterm delivery, amniotic fluid infection, histologic chorioamnionitis, and chorioamnion infection. *Obstet Gynecol*. 1993;81(6):941-948.
81. Arntzen KJ, Kjollesdal AM, Halgunset J, Vatten L, Austgulen R. TNF, IL-1, IL-6, IL-8 and soluble TNF receptors in relation to chorioamnionitis and premature labor. *J Perinat Med*. 1998;26(1):17-26.
82. Yoon BH, Jun JK, Romero R, et al. Amniotic fluid inflammatory cytokines (interleukin-6, interleukin-1beta, and tumor necrosis factor-alpha), neonatal brain white matter lesions, and cerebral palsy. *Am J Obstet Gynecol*. 1997;177(1):19-26.
83. Yoon BH, Romero R, Jun JK, et al. Amniotic fluid cytokines (interleukin-6, tumor necrosis factor-alpha, interleukin-1 beta, and interleukin-8) and the risk for the development of bronchopulmonary dysplasia. *Am J Obstet Gynecol*. 1997;177(4):825-830.
84. Figueroa R, Garry D, Elimian A, Patel K, Sehgal PB, Tejani N. Evaluation of amniotic fluid cytokines in preterm labor and intact membranes. *J Matern Fetal Neonatal Med*. 2005;18(4):241-247.
85. Holst RM, Laurini R, Jacobsson B, et al. Expression of cytokines and chemokines in cervical and amniotic fluid: relationship to histological chorioamnionitis. *J Matern Fetal Neonatal Med*. 2007;20(12):885-893.
86. Kacerovsky M, Celec P, Vlkova B, et al. Amniotic fluid protein profiles of intraamniotic inflammatory response to *Ureaplasma* spp. and other bacteria. *PLoS One*. 2013;8(3):e60399.
87. Bhat G, Williams SM, Saade GR, Menon R. Biomarker interactions are better predictors of spontaneous preterm birth. *Reprod Sci*. 2014;21(3):340-350.
88. Romero R, Grivel JC, Tarca AL, et al. Evidence of perturbations of the cytokine network in preterm labor. *Am J Obstet Gynecol*. 2015;213(6):836.e831-836.e818.
89. Saito M, Payne MS, Miura Y, et al. Polymyxin B agonist capture therapy for intrauterine inflammation: proof-of-principle in a fetal ovine model. *Reprod Sci*. 2014;21(5):623-631.
90. Lockwood CJ, Arcuri F, Toti P, et al. Tumor necrosis factor-alpha and interleukin-1beta regulate interleukin-8 expression in third trimester decidual cells: implications for the genesis of chorioamnionitis. *Am J Pathol*. 2006;169(4):1294-1302.
91. Lockwood CJ, Murk WK, Kayisli UA, et al. Regulation of interleukin-6 expression in human decidual cells and its potential role in chorioamnionitis. *Am J Pathol*. 2010;177(4):1755-1764.
92. Yoon BH, Romero R, Yang SH, et al. Interleukin-6 concentrations in umbilical cord plasma are elevated in neonates with white matter lesions associated with periventricular leukomalacia. *Am J Obstet Gynecol*. 1996;174(5):1433-1440.
93. Dollner H, Vatten L, Halgunset J, Rahimipour S, Austgulen R. Histologic chorioamnionitis and umbilical serum levels of pro-inflammatory cytokines and cytokine inhibitors. *BJOG*. 2002;109(5):534-539.
94. Andrys C, Drahosova M, Hornychova H, et al. Umbilical cord blood concentrations of IL-6, IL-8, and MMP-8 in pregnancy complicated by preterm premature rupture of the membranes and histological chorioamnionitis. *Neuro Endocrinol Lett*. 2010;31(6):857-863.
95. Saito S, Kasahara T, Kato Y, Ishihara Y, Ichijo M. Elevation of amniotic fluid interleukin 6 (IL-6), IL-8 and granulocyte colony stimulating factor (G-CSF) in term and preterm parturition. *Cytokine*. 1993;5(1):81-88.
96. Yoon BH, Romero R, Park JS, et al. Fetal exposure to an intra-amniotic inflammation and the development of cerebral palsy at the age of three years. *Am J Obstet Gynecol*. 2000;182(3):675-681.
97. Hitti J, Tarczy-Hornoch P, Murphy J, Hillier SL, Aura J, Eschenbach DA. Amniotic fluid infection, cytokines, and adverse outcome among infants at 34 weeks' gestation or less. *Obstet Gynecol*. 2001;98(6):1080-1088.
98. Moon JB, Kim JC, Yoon BH, et al. Amniotic fluid matrix metalloproteinase-8 and the development of cerebral palsy. *J Perinat Med*. 2002;30(4):301-306.
99. Combs CA, Gravett M, Garite TJ, et al. Amniotic fluid infection, inflammation, and colonization in preterm labor with intact membranes. *Am J Obstet Gynecol*. 2014;210(2):125.e121-125.e115.
100. Kunze M, Klar M, Morfeld CA, et al. Cytokines in noninvasively obtained amniotic fluid as predictors of fetal inflammatory response syndrome. *Am J Obstet Gynecol*. 2016;215(1):96.e1-96.e8.
101. Weeks JW, Reynolds L, Taylor D, Lewis J, Wan T, Gall SA. Umbilical cord blood interleukin-6 levels and neonatal morbidity. *Obstet Gynecol*. 1997;90(5):815-818.
102. Gomez R, Romero R, Ghezzi F, Yoon BH, Mazor M, Berry SM. The fetal inflammatory response syndrome. *Am J Obstet Gynecol*. 1998;179(1):194-202.
103. Berner R, Niemeyer CM, Leititis JU, et al. Plasma levels and gene expression of granulocyte colony-stimulating factor, tumor necrosis factor-alpha, interleukin (IL)-1beta, IL-6, IL-8, and soluble intercellular adhesion molecule-1 in neonatal early onset sepsis. *Pediatr Res*. 1998;44(4):469-477.
104. Dollner H, Vatten L, Linnebo I, Zanussi GF, Laerdal A, Austgulen R. Inflammatory mediators in umbilical plasma from neonates who develop early-onset sepsis. *Biol Neonate*. 2001;80(1):41-47.
105. Goepfert AR, Andrews WW, Carlo W, et al. Umbilical cord plasma interleukin-6 concentrations in preterm infants and risk of neonatal morbidity. *Am J Obstet Gynecol*. 2004;191(4):1375-1381.
106. An H, Nishimaki S, Ohyama M, et al. Interleukin-6, interleukin-8, and soluble tumor necrosis factor receptor-I in the cord blood as predictors of chronic lung disease in premature infants. *Am J Obstet Gynecol*. 2004;191(5):1649-1654.
107. Elsmen E, Ley D, Cilio CM, Hansen-Pupp I, Hellstrom-Westas L. Umbilical cord levels of interleukin-1 receptor antagonist and neonatal outcome. *Biol Neonate*. 2006;89(4):220-226.

108. Satar M, Turhan E, Yapicioglu H, Narli N, Ozgunen FT, Cetiner S. Cord blood cytokine levels in neonates born to mothers with prolonged premature rupture of membranes and its relationship with morbidity and mortality. *Eur Cytokine Netw.* 2008;19(1):37-41.
109. Liu J, Feng ZC. Increased umbilical cord plasma interleukin-1 beta levels was correlated with adverse outcomes of neonatal hypoxic-ischemic encephalopathy. *J Trop Pediatr.* 2010;56(3):178-182.
110. Armstrong-Wells J, Donnelly M, Post MD, Manco-Johnson MJ, Winn VD, Sebire G. Inflammatory predictors of neurologic disability after preterm premature rupture of membranes. *Am J Obstet Gynecol.* 2015;212(2):212.e211-212.e219.
111. Cordeiro CN, Savva Y, Vaidya D, et al. Mathematical modeling of the biomarker milieu to characterize preterm birth and predict adverse neonatal outcomes. *Am J Reprod Immunol.* 2016;75(5):594-601.
112. Pineles BL, Romero R, Montenegro D, et al. "The inflammasome" in human parturition. *Reprod Sci.* 2007;14(1):59A.
113. Gotsch F, Romero R, Chaiworapongsa T, et al. Evidence of the involvement of caspase-1 under physiologic and pathologic cellular stress during human pregnancy: a link between the inflammasome and parturition. *J Matern Fetal Neonatal Med.* 2008;21(9):605-616.
114. Romero R, Xu Y, Plazyo O, et al. A role for the inflammasome in spontaneous labor at term [published online March 8, 2016]. *Am J Reprod Immunol.* doi:10.1111/aji.12440.
115. Gomez-Lopez N, Romero R, Xu Y, et al. A role for the inflammasome in spontaneous labor at term with acute histologic chorioamnionitis [published online November 16, 2016]. pii: 1933719116675058.
116. Martinon F, Burns K, Tschopp J. The inflammasome: a molecular platform triggering activation of inflammatory caspases and processing of proIL-beta. *Mol Cell.* 2002;10(2):417-426.
117. Petrilli V, Papin S, Tschopp J. The inflammasome. *Curr Biol.* 2005;15(15):R581.
118. Ogura Y, Sutterwala FS, Flavell RA. The inflammasome: first line of the immune response to cell stress. *Cell.* 2006;126(4):659-662.
119. Sutterwala FS, Ogura Y, Flavell RA. The inflammasome in pathogen recognition and inflammation. *J Leukoc Biol.* 2007;82(2):259-264.
120. Mariathasan S, Monack DM. Inflammasome adaptors and sensors: intracellular regulators of infection and inflammation. *Nat Rev Immunol.* 2007;7(1):31-40.
121. Stutz A, Golenbock DT, Latz E. Inflammasomes: too big to miss. *J Clin Invest.* 2009;119(12):3502-3511.
122. Franchi L, Eigenbrod T, Munoz-Planillo R, Nunez G. The inflammasome: a caspase-1-activation platform that regulates immune responses and disease pathogenesis. *Nat Immunol.* 2009;10(3):241-247.
123. Jha S, Ting JP. Inflammasome-associated nucleotide-binding domain, leucine-rich repeat proteins and inflammatory diseases. *J Immunol.* 2009;183(12):7623-7629.
124. Pedra JH, Cassel SL, Sutterwala FS. Sensing pathogens and danger signals by the inflammasome. *Curr Opin Immunol.* 2009;21(1):10-16.
125. Lamkanfi M, Dixit VM. Inflammasomes: guardians of cytosolic sanctity. *Immunol Rev.* 2009;227(1):95-105.
126. Latz E. The inflammasomes: mechanisms of activation and function. *Curr Opin Immunol.* 2010;22(1):28-33.
127. Schroder K, Tschopp J. The inflammasomes. *Cell.* 2010;140(6):821-832.
128. Franchi L, Munoz-Planillo R, Reimer T, Eigenbrod T, Nunez G. Inflammasomes as microbial sensors. *Eur J Immunol.* 2010;40(3):611-615.
129. Bauernfeind F, Ablasser A, Bartok E, et al. Inflammasomes: current understanding and open questions. *Cell Mol Life Sci.* 2011;68(5):765-783.
130. Kersse K, Bertrand MJ, Lamkanfi M, Vandenabeele P. NOD-like receptors and the innate immune system: coping with danger, damage and death. *Cytokine Growth Factor Rev.* 2011;22(5-6):257-276.
131. Gross O, Thomas CJ, Guarda G, Tschopp J. The inflammasome: an integrated view. *Immunol Rev.* 2011;243(1):136-151.
132. Lamkanfi M. Emerging inflammasome effector mechanisms. *Nat Rev Immunol.* 2011;11(3):213-220.
133. Lamkanfi M, Dixit VM. Modulation of inflammasome pathways by bacterial and viral pathogens. *J Immunol.* 2011;187(2):597-602.
134. Broz P, Monack DM. Molecular mechanisms of inflammasome activation during microbial infections. *Immunol Rev.* 2011;243(1):174-190.
135. Skeldon A, Saleh M. The inflammasomes: molecular effectors of host resistance against bacterial, viral, parasitic, and fungal infections. *Front Microbiol.* 2011;2:15.
136. Horvath GL, Schrum JE, De Nardo CM, Latz E. Intracellular sensing of microbes and danger signals by the inflammasomes. *Immunol Rev.* 2011;243(1):119-135.
137. van de Veerdonk FL, Netea MG, Dinarello CA, Joosten LA. Inflammasome activation and IL-1beta and IL-18 processing during infection. *Trends Immunol.* 2011;32(3):110-116.
138. Franchi L, Munoz-Planillo R, Nunez G. Sensing and reacting to microbes through the inflammasomes. *Nat Immunol.* 2012;13(4):325-332.
139. Dagenais M, Skeldon A, Saleh M. The inflammasome: in memory of Dr. Jurg Tschopp. *Cell Death Differ.* 2012;19(1):5-12.
140. Ciraci C, Janczy JR, Sutterwala FS, Cassel SL. Control of innate and adaptive immunity by the inflammasome. *Microbes Infect.* 2012;14(14):1263-1270.
141. Rathinam VA, Vanaja SK, Fitzgerald KA. Regulation of inflammasome signaling. *Nat Immunol.* 2012;13(4):333-332.
142. Franchi L, Nunez G. Immunology. Orchestrating inflammasomes. *Science.* 2012;337(6100):1299-1300.
143. Henao-Mejia J, Elinav E, Strowig T, Flavell RA. Inflammasomes: far beyond inflammation. *Nat Immunol.* 2012;13(4):321-324.
144. Latz E, Xiao TS, Stutz A. Activation and regulation of the inflammasomes. *Nat Rev Immunol.* 2013;13(6):397-411.
145. Bauernfeind F, Hornung V. Of inflammasomes and pathogens – sensing of microbes by the inflammasome. *EMBO Mol Med.* 2013;5(6):814-826.
146. Vladimer GI, Marty-Roix R, Ghosh S, Weng D, Lien E. Inflammasomes and host defenses against bacterial infections. *Curr Opin Microbiol.* 2013;16(1):23-31.

147. Lamkanfi M, Dixit VM. Mechanisms and functions of inflammasomes. *Cell*. 2014;157(5):1013-1022.
148. Ulland TK, Ferguson PJ, Sutterwala FS. Evasion of inflammasome activation by microbial pathogens. *J Clin Invest*. 2015;125(2):469-477.
149. Vanaja SK, Rathinam VA, Fitzgerald KA. Mechanisms of inflammasome activation: recent advances and novel insights. *Trends Cell Biol*. 2015;25(5):308-315.
150. Guo H, Callaway JB, Ting JP. Inflammasomes: mechanism of action, role in disease, and therapeutics. *Nat Med*. 2015;21(7):677-687.
151. Agostini L, Martinon F, Burns K, McDermott MF, Hawkins PN, Tschopp J. NALP3 forms an IL-1beta-processing inflammasome with increased activity in Muckle-Wells autoinflammatory disorder. *Immunity*. 2004;20(3):319-325.
152. Mariathasan S, Newton K, Monack DM, et al. Differential activation of the inflammasome by caspase-1 adaptors ASC and Ipaf. *Nature*. 2004;430(6996):213-218.
153. Black RA, Kronheim SR, Merriam JE, March CJ, Hopp TP. A pre-aspartate-specific protease from human leukocytes that cleaves pro-interleukin-1 beta. *J Biol Chem*. 1989;264(10):5323-5326.
154. Kostura MJ, Tocci MJ, Limjuco G, et al. Identification of a monocyte specific pre-interleukin 1 beta convertase activity. *Proc Natl Acad Sci U S A*. 1989;86(14):5227-5231.
155. Thornberry NA, Bull HG, Calaycay JR, et al. A novel heterodimeric cysteine protease is required for interleukin-1 beta processing in monocytes. *Nature*. 1992;356(6372):768-774.
156. Cerretti DP, Kozlosky CJ, Mosley B, et al. Molecular cloning of the interleukin-1 beta converting enzyme. *Science*. 1992;256(5053):97-100.
157. Gu Y, Kuida K, Tsutsui H, et al. Activation of interferon-gamma inducing factor mediated by interleukin-1beta converting enzyme. *Science*. 1997;275(5297):206-209.
158. Ghayur T, Banerjee S, Hugunin M, et al. Caspase-1 processes IFN-gamma-inducing factor and regulates LPS-induced IFN-gamma production. *Nature*. 1997;386(6625):619-623.
159. Dinarello CA. Interleukin-1 beta, interleukin-18, and the interleukin-1 beta converting enzyme. *Ann N Y Acad Sci*. 1998;856:1-11.
160. Fantuzzi G, Dinarello CA. Interleukin-18 and interleukin-1 beta: two cytokine substrates for ICE (caspase-1). *J Clin Immunol*. 1999;19(1):1-11.
161. Sansonetti PJ, Phalipon A, Arondel J, et al. Caspase-1 activation of IL-1beta and IL-18 are essential for Shigella flexneri-induced inflammation. *Immunity*. 2000;12(5):581-590.
162. Kahlenberg JM, Lundberg KC, Kertesz SB, Qu Y, Dubyak GR. Potentiation of caspase-1 activation by the P2X7 receptor is dependent on TLR signals and requires NF-kappaB-driven protein synthesis. *J Immunol*. 2005;175(11):7611-7622.
163. Netea MG, van de Veerdonk FL, van der Meer JW, Dinarello CA, Joosten LA. Inflammasome-independent regulation of IL-1-family cytokines. *Annu Rev Immunol*. 2015;33:49-77.
164. Cookson BT, Brennan MA. Pro-inflammatory programmed cell death. *Trends Microbiol*. 2001;9(3):113-114.
165. Miao EA, Rajan JV, Aderem A. Caspase-1-induced pyroptotic cell death. *Immunol Rev*. 2011;243(1):206-214.
166. Shalini S, Dorstyn L, Dawar S, Kumar S. Old, new and emerging functions of caspases. *Cell Death Differ*. 2015;22(4):526-539.
167. Wang S, Miura M, Jung YK, Zhu H, Li E, Yuan J. Murine caspase-11, an ICE-interacting protease, is essential for the activation of ICE. *Cell*. 1998;92(4):501-509.
168. Sollberger G, Strittmatter GE, Kistowska M, French LE, Beer HD. Caspase-4 is required for activation of inflammasomes. *J Immunol*. 2012;188(4):1992-2000.
169. Kayagaki N, Wong MT, Stowe IB, et al. Noncanonical inflammasome activation by intracellular LPS independent of TLR4. *Science*. 2013;341(6151):1246-1249.
170. Hagar JA, Powell DA, Aachoui Y, Ernst RK, Miao EA. Cytoplasmic LPS activates caspase-11: implications in TLR4-independent endotoxic shock. *Science*. 2013;341(6151):1250-1253.
171. Aachoui Y, Leaf IA, Hagar JA, et al. Caspase-11 protects against bacteria that escape the vacuole. *Science*. 2013;339(6122):975-978.
172. Kayagaki N, Warming S, Lamkanfi M, et al. Non-canonical inflammasome activation targets caspase-11. *Nature*. 2011;479(7371):117-121.
173. Pacora P, Romero R, Maymon E, et al. Participation of the novel cytokine interleukin 18 in the host response to intra-amniotic infection. *Am J Obstet Gynecol*. 2000;183(5):1138-1143.
174. Hoang M, Potter JA, Gysler SM, et al. Human fetal membranes generate distinct cytokine profiles in response to bacterial Toll-like receptor and nod-like receptor agonists. *Biol Reprod*. 2014;90(2):39.
175. Martinon F, Tschopp J. Inflammatory caspases: linking an intracellular innate immune system to autoinflammatory diseases. *Cell*. 2004;117(5):561-574.
176. Martinon F, Tschopp J. Inflammatory caspases and inflammasomes: master switches of inflammation. *Cell Death Differ*. 2007;14(1):10-22.
177. Case CL, Kohler LJ, Lima JB, et al. Caspase-11 stimulates rapid flagellin-independent pyroptosis in response to Legionella pneumophila. *Proc Natl Acad Sci U S A*. 2013;110(5):1851-1856.
178. Broz P, Monack DM. Noncanonical inflammasomes: caspase-11 activation and effector mechanisms. *PLoS Pathog*. 2013;9(2):e1003144.
179. Knodler LA, Crowley SM, Sham HP, et al. Noncanonical inflammasome activation of caspase-4/caspase-11 mediates epithelial defenses against enteric bacterial pathogens. *Cell Host Microbe*. 2014;16(2):249-256.
180. Casson CN, Yu J, Reyes VM, et al. Human caspase-4 mediates noncanonical inflammasome activation against gram-negative bacterial pathogens. *Proc Natl Acad Sci U S A*. 2015;112(21):6688-6693.
181. Yang D, He Y, Munoz-Planillo R, Liu Q, Nunez G. Caspase-11 requires the pannexin-1 channel and the purinergic P2X7 pore to mediate pyroptosis and endotoxic shock. *Immunity*. 2015;43(5):923-932.
182. Sutterwala FS, Haasken S, Cassel SL. Mechanism of NLRP3 inflammasome activation. *Ann N Y Acad Sci*. 2014;1319:82-95.

183. Sutterwala FS, Ogura Y, Zamboni DS, Roy CR, Flavell RA. NALP3: a key player in caspase-1 activation. *J Endotoxin Res.* 2006;12(4):251-256.
184. Chae JJ, Cho YH, Lee GS, et al. Gain-of-function pyrin mutations induce NLRP3 protein-independent interleukin-1beta activation and severe autoinflammation in mice. *Immunity.* 2011;34(5):755-768.
185. Dostert C, Petrilli V, Van Bruggen R, Steele C, Mossman BT, Tschopp J. Innate immune activation through Nalp3 inflammasome sensing of asbestos and silica. *Science.* 2008;320(5876):674-677.
186. Cassel SL, Eisenbarth SC, Iyer SS, et al. The Nalp3 inflammasome is essential for the development of silicosis. *Proc Natl Acad Sci U S A.* 2008;105(26):9035-9040.
187. Hornung V, Bauernfeind F, Halle A, et al. Silica crystals and aluminum salts activate the NALP3 inflammasome through phagosomal destabilization. *Nat Immunol.* 2008;9(8):847-856.
188. Yamasaki K, Muto J, Taylor KR, et al. NLRP3/cryopyrin is necessary for interleukin-1beta (IL-1beta) release in response to hyaluronan, an endogenous trigger of inflammation in response to injury. *J Biol Chem.* 2009;284(19):12762-12771.
189. Cassel SL, Joly S, Sutterwala FS. The NLRP3 inflammasome: a sensor of immune danger signals. *Semin Immunol.* 2009;21(4):194-198.
190. Cassel SL, Sutterwala FS. Sterile inflammatory responses mediated by the NLRP3 inflammasome. *Eur J Immunol.* 2010;40(3):607-611.
191. Leemans JC, Cassel SL, Sutterwala FS. Sensing damage by the NLRP3 inflammasome. *Immunol Rev.* 2011;243(1):152-162.
192. Martinon F, Petrilli V, Mayor A, Tardivel A, Tschopp J. Gout-associated uric acid crystals activate the NALP3 inflammasome. *Nature.* 2006;440(7081):237-241.
193. Mariathasan S, Weiss DS, Newton K, et al. Cryopyrin activates the inflammasome in response to toxins and ATP. *Nature.* 2006;440(7081):228-232.
194. Kool M, Petrilli V, De Smedt T, et al. Cutting edge: alum adjuvant stimulates inflammatory dendritic cells through activation of the NALP3 inflammasome. *J Immunol.* 2008;181(6):3755-3759.
195. Li H, Willingham SB, Ting JP, Re F. Cutting edge: inflammasome activation by alum and alum's adjuvant effect are mediated by NLRP3. *J Immunol.* 2008;181(1):17-21.
196. Eisenbarth SC, Colegio OR, O'Connor W, Sutterwala FS, Flavell RA. Crucial role for the Nalp3 inflammasome in the immunostimulatory properties of aluminium adjuvants. *Nature.* 2008;453(7198):1122-1126.
197. Franchi L, Nunez G. The NLRP3 inflammasome is critical for aluminium hydroxide-mediated IL-1beta secretion but dispensable for adjuvant activity. *Eur J Immunol.* 2008;38(8):2085-2089.
198. Demento SL, Eisenbarth SC, Foellmer HG, et al. Inflammasome-activating nanoparticles as modular systems for optimizing vaccine efficacy. *Vaccine.* 2009;27(23):3013-3021.
199. Nakahira K, Haspel JA, Rathinam VA, et al. Autophagy proteins regulate innate immune responses by inhibiting the release of mitochondrial DNA mediated by the NALP3 inflammasome. *Nat Immunol.* 2011;12(3):222-230.
200. Iyer SS, He Q, Janczy JR, et al. Mitochondrial cardiolipin is required for NLRP3 inflammasome activation. *Immunity.* 2013;39(2):311-323.
201. O'Neill LA. Cardiolipin and the NLRP3 inflammasome. *Cell Metab.* 2013;18(5):610-612.
202. Gurcel L, Abrami L, Girardin S, Tschopp J, van der Goot FG. Caspase-1 activation of lipid metabolic pathways in response to bacterial pore-forming toxins promotes cell survival. *Cell.* 2006;126(6):1135-1145.
203. Munoz-Planillo R, Franchi L, Miller LS, Nunez G. A critical role for hemolysins and bacterial lipoproteins in *Staphylococcus aureus*-induced activation of the NLRP3 inflammasome. *J Immunol.* 2009;183(6):3942-3948.
204. Kanneganti TD, Body-Malapel M, Amer A, et al. Critical role for cryopyrin/Nalp3 in activation of caspase-1 in response to viral infection and double-stranded RNA. *J Biol Chem.* 2006;281(48):36560-36568.
205. Koo IC, Wang C, Raghavan S, Morisaki JH, Cox JS, Brown EJ. ESX-1-dependent cytolysis in lysosome secretion and inflammasome activation during mycobacterial infection. *Cell Microbiol.* 2008;10(9):1866-1878.
206. Muruve DA, Petrilli V, Zaiss AK, et al. The inflammasome recognizes cytosolic microbial and host DNA and triggers an innate immune response. *Nature.* 2008;452(7183):103-107.
207. Thomas PG, Dash P, Aldridge JR Jr, et al. The intracellular sensor NLRP3 mediates key innate and healing responses to influenza A virus via the regulation of caspase-1. *Immunity.* 2009;30(4):566-575.
208. Allen IC, Scull MA, Moore CB, et al. The NLRP3 inflammasome mediates in vivo innate immunity to influenza A virus through recognition of viral RNA. *Immunity.* 2009;30(4):556-565.
209. Duncan JA, Gao X, Huang MT, et al. Neisseria gonorrhoeae activates the proteinase cathepsin B to mediate the signaling activities of the NLRP3 and ASC-containing inflammasome. *J Immunol.* 2009;182(10):6460-6469.
210. Joly S, Ma N, Sadler JJ, Soll DR, Cassel SL, Sutterwala FS. Cutting edge: *Candida albicans* hyphae formation triggers activation of the NLRP3 inflammasome. *J Immunol.* 2009;183(6):3578-3581.
211. Ichinohe T, Lee HK, Ogura Y, Flavell R, Iwasaki A. Inflammasome recognition of influenza virus is essential for adaptive immune responses. *J Exp Med.* 2009;206(1):79-87.
212. Menu P, Vince JE. The NLRP3 inflammasome in health and disease: the good, the bad and the ugly. *Clin Exp Immunol.* 2011;166(1):1-15.
213. Rathinam VA, Vanaja SK, Waggoner L, et al. TRIF licenses caspase-11-dependent NLRP3 inflammasome activation by gram-negative bacteria. *Cell.* 2012;150(3):606-619.
214. Clay GM, Sutterwala FS, Wilson ME. NLR proteins and parasitic disease. *Immunol Res.* 2014;59(1-3):142-152.
215. Bauernfeind FG, Horvath G, Stutz A, et al. Cutting edge: NF-kappaB activating pattern recognition and cytokine receptors license NLRP3 inflammasome activation by regulating NLRP3 expression. *J Immunol.* 2009;183(2):787-791.

216. Franchi L, Eigenbrod T, Nunez G. Cutting edge: TNF- α mediates sensitization to ATP and silica via the NLRP3 inflammasome in the absence of microbial stimulation. *J Immunol.* 2009;183(2):792-796.
217. Fernandes-Alnemri T, Wu J, Yu JW, et al. The pyroptosome: a supramolecular assembly of ASC dimers mediating inflammatory cell death via caspase-1 activation. *Cell Death Differ.* 2007;14(9):1590-1604.
218. Jaiswal MK, Agrawal V, Mallers T, Gilman-Sachs A, Hirsch E, Beaman KD. Regulation of apoptosis and innate immune stimuli in inflammation-induced preterm labor. *J Immunol.* 2013;191(11):5702-5713.
219. Broz P, Ruby T, Belhocine K, et al. Caspase-11 increases susceptibility to Salmonella infection in the absence of caspase-1. *Nature.* 2012;490(7419):288-291.
220. Romero R, Chaiworapongsa T, Alpay Savasan Z, et al. Damage-associated molecular patterns (DAMPs) in preterm labor with intact membranes and preterm PROM: a study of the alarmin HMGB1. *J Matern Fetal Neonatal Med.* 2011;24(12):1444-1455.
221. Gomez-Lopez N, Romero R, Plazyo O, et al. Intra-amniotic administration of HMGB1 induces spontaneous preterm labor and birth. *Am J Reprod Immunol.* 2016;75(1):3-7.
222. Wilson KP, Black JA, Thomson JA, et al. Structure and mechanism of interleukin-1 beta converting enzyme. *Nature.* 1994;370(6487):270-275.
223. Dinarello CA. Interleukin-1. *Adv Pharmacol.* 1994;25:21-51.
224. Dinarello CA. The biological properties of interleukin-1. *Eur Cytokine Netw.* 1994;5(6):517-531.
225. Dinarello CA. The interleukin-1 family: 10 years of discovery. *FASEB J.* 1994;8(15):1314-1325.
226. Dinarello CA. Interleukin-1. *Cytokine Growth Factor Rev.* 1997;8(4):253-265.
227. Dinarello CA. Immunological and inflammatory functions of the interleukin-1 family. *Annu Rev Immunol.* 2009;27:519-550.
228. Creagh EM. Caspase crosstalk: integration of apoptotic and innate immune signalling pathways. *Trends Immunol.* 2014;35(12):631-640.
229. Romero R, Durum S, Dinarello CA, Oyarzun E, Hobbins JC, Mitchell MD. Interleukin-1 stimulates prostaglandin biosynthesis by human amnion. *Prostaglandins.* 1989;37(1):13-22.
230. Hertelendy F, Romero R, Molnar M, Todd H, Baldassare JJ. Cytokine-initiated signal transduction in human myometrial cells. *Am J Reprod Immunol.* 1993;30(2-3):49-57.
231. Hertelendy F, Rastogi P, Molnar M, Romero R. Interleukin-1 β -induced prostaglandin E2 production in human myometrial cells: role of a pertussis toxin-sensitive component. *Am J Reprod Immunol.* 2001;45(3):142-147.
232. Belt AR, Baldassare JJ, Molnar M, Romero R, Hertelendy F. The nuclear transcription factor NF- κ B mediates interleukin-1 β -induced expression of cyclooxygenase-2 in human myometrial cells. *Am J Obstet Gynecol.* 1999;181(2):359-366.
233. Watari M, Watari H, DiSanto ME, Chacko S, Shi GP, Strauss JF 3rd. Pro-inflammatory cytokines induce expression of matrix-metabolizing enzymes in human cervical smooth muscle cells. *Am J Pathol.* 1999;154(6):1755-1762.
234. Heng YJ, Liong S, Permezel M, Rice GE, Di Quinzio MK, Georgiou HM. The interplay of the interleukin 1 system in pregnancy and labor. *Reprod Sci.* 2014;21(1):122-130.
235. Stock O, Gordon L, Kapoor J, et al. Chorioamnionitis occurring in women with preterm rupture of the fetal membranes is associated with a dynamic increase in mRNAs coding cytokines in the maternal circulation. *Reprod Sci.* 2015;22(7):852-859.
236. Romero R, Mazor M, Tartakovsky B. Systemic administration of interleukin-1 induces preterm parturition in mice. *Am J Obstet Gynecol.* 1991;165(4 pt 1):969-971.
237. Romero R, Sepulveda W, Mazor M, et al. The natural interleukin-1 receptor antagonist in term and preterm parturition. *Am J Obstet Gynecol.* 1992;167(4 pt 1):863-872.
238. Gravett MG, Witkin SS, Haluska GJ, Edwards JL, Cook MJ, Novy MJ. An experimental model for intraamniotic infection and preterm labor in rhesus monkeys. *Am J Obstet Gynecol.* 1994;171(6):1660-1667.
239. Witkin SS, Gravett MG, Haluska GJ, Novy MJ. Induction of interleukin-1 receptor antagonist in rhesus monkeys after intraamniotic infection with group B streptococci or interleukin-1 infusion. *Am J Obstet Gynecol.* 1994;171(6):1668-1672.
240. Baggia S, Gravett MG, Witkin SS, Haluska GJ, Novy MJ. Interleukin-1 beta intra-amniotic infusion induces tumor necrosis factor- α , prostaglandin production, and preterm contractions in pregnant rhesus monkeys. *J Soc Gynecol Investig.* 1996;3(3):121-126.
241. Vadillo-Ortega F, Sadowsky DW, Haluska GJ, et al. Identification of matrix metalloproteinase-9 in amniotic fluid and amniochorion in spontaneous labor and after experimental intrauterine infection or interleukin-1 beta infusion in pregnant rhesus monkeys. *Am J Obstet Gynecol.* 2002;186(1):128-138.
242. Sadowsky DW, Adams KM, Gravett MG, Witkin SS, Novy MJ. Preterm labor is induced by intraamniotic infusions of interleukin-1 β and tumor necrosis factor- α but not by interleukin-6 or interleukin-8 in a nonhuman primate model. *Am J Obstet Gynecol.* 2006;195(6):1578-1589.
243. Aagaard K, Ganu R, Ma J, et al. Intraamniotic interleukin-1 (IL1 β) induces histological chorioamnionitis and alters the microbiome in a primate model of inflammatory preterm birth. *Am J Obstet Gynecol.* 2014;208(1):S218.
244. Prince A, Ma J, Miller L, et al. Chorioamnionitis induced by intraamniotic injection of IL1, LPS or *Ureaplasma parvum* is associated with an altered microbiome in a primate model of inflammatory preterm birth. *Am J Obstet Gynecol.* 2014;212(1):S153.
245. Presicce P, Senthamaraikannan P, Alvarez M, et al. Neutrophil recruitment and activation in decidua with intra-amniotic IL-1 β in the preterm rhesus macaque. *Biol Reprod.* 2015;92(2):56.
246. Jacobsson B, Holst RM, Mattsby-Baltzer I, Nikolaitchouk N, Wennerholm UB, Hagberg H. Interleukin-18 in cervical mucus and amniotic fluid: relationship to microbial invasion of the amniotic fluid, intra-amniotic inflammation and preterm delivery. *BJOG.* 2003;110(6):598-603.
247. Okamura H, Tsutsi H, Komatsu T, et al. Cloning of a new cytokine that induces IFN- γ production by T cells. *Nature.* 1995;378(6552):88-91.

248. Ushio S, Namba M, Okura T, et al. Cloning of the cDNA for human IFN-gamma-inducing factor, expression in *Escherichia coli*, and studies on the biologic activities of the protein. *J Immunol.* 1996;156(11):4274-4279.
249. Takeda K, Tsutsui H, Yoshimoto T, et al. Defective NK cell activity and Th1 response in IL-18-deficient mice. *Immunity.* 1998;8(3):383-390.
250. Dinarello CA, Novick D, Puren AJ, et al. Overview of interleukin-18: more than an interferon-gamma inducing factor. *J Leukoc Biol.* 1998;63(6):658-664.
251. Dinarello CA. IL-18: A TH1-inducing, proinflammatory cytokine and new member of the IL-1 family. *J Allergy Clin Immunol.* 1999;103(1 pt 1):11-24.
252. Dinarello CA. Interleukin-18. *Methods.* 1999;19(1):121-132.
253. Novick D, Kim S, Kaplanski G, Dinarello CA. Interleukin-18, more than a Th1 cytokine. *Semin Immunol.* 2013;25(6):439-448.
254. Dinarello CA, Novick D, Kim S, Kaplanski G. Interleukin-18 and IL-18 Binding Protein. *Front Immunol.* 2013;4:289.